

Burn contractures Surgery

Revue of 246 cases

Crescenzo D'Onofrio-Paideia Hospital, Rome-Italy

Gianfranco Morino-Mbagathi Hospital, Nairobi-Kenya

Antonio Melotto-Giussano Hospital, Milan-Italy



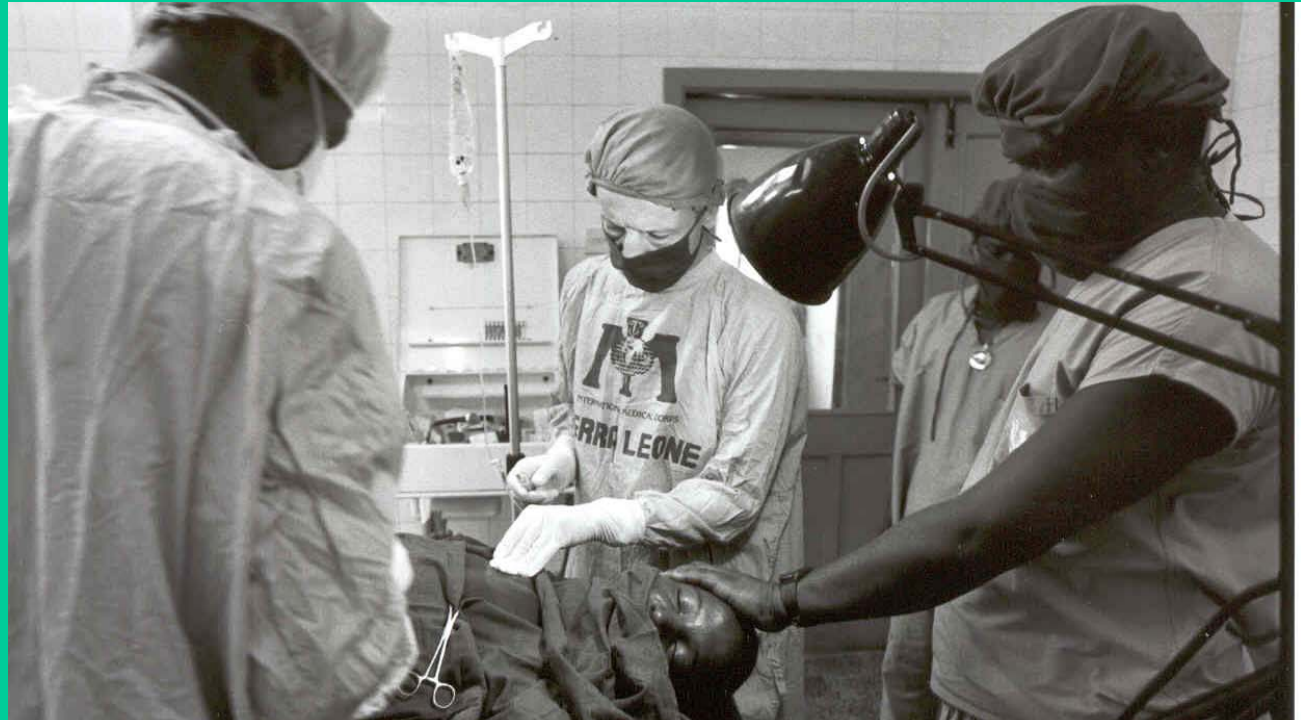
Burn reconstruction performed in:

Mozambique-1999

Bangladesh-2000-2001

Sierra Leone-2001-20002

Kenya-2003



Developed projects

Comboni Missionaries Project in Mozambique

MAE-COOPI Project in Bangladesh (Funded by Italian Foreign Office - International Cooperation)

UNICEF-IMC Project in Sierra Leone(Funded by United Nations Children Agency - International Medical Corps)

MAE-CCM Project in Kenya(Funded by Italian Foreign Office - Medical Collaboration Committee)



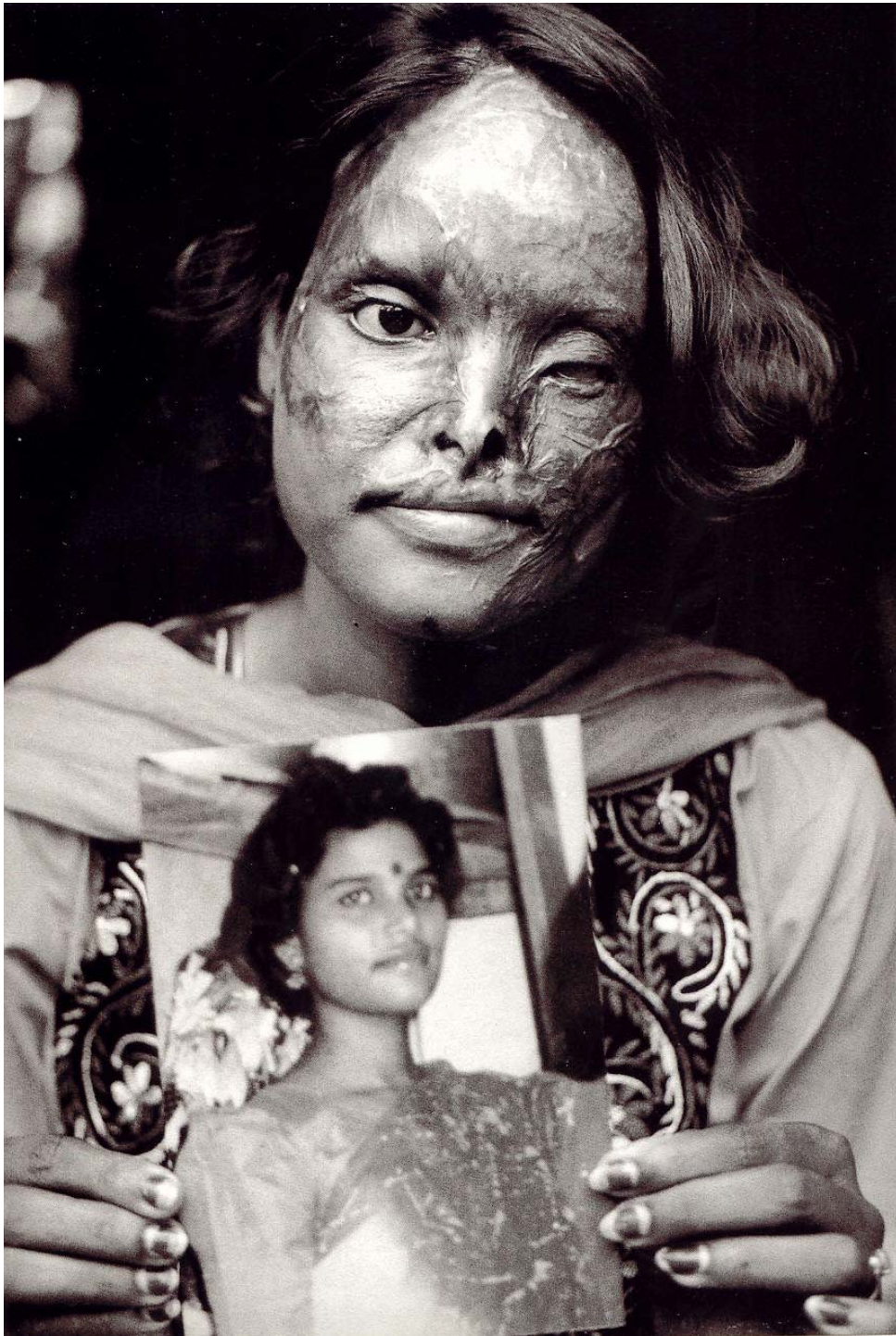
FEDERICO
MOTTA
EDITORE

I volti negati

reportage
dal Bangladesh

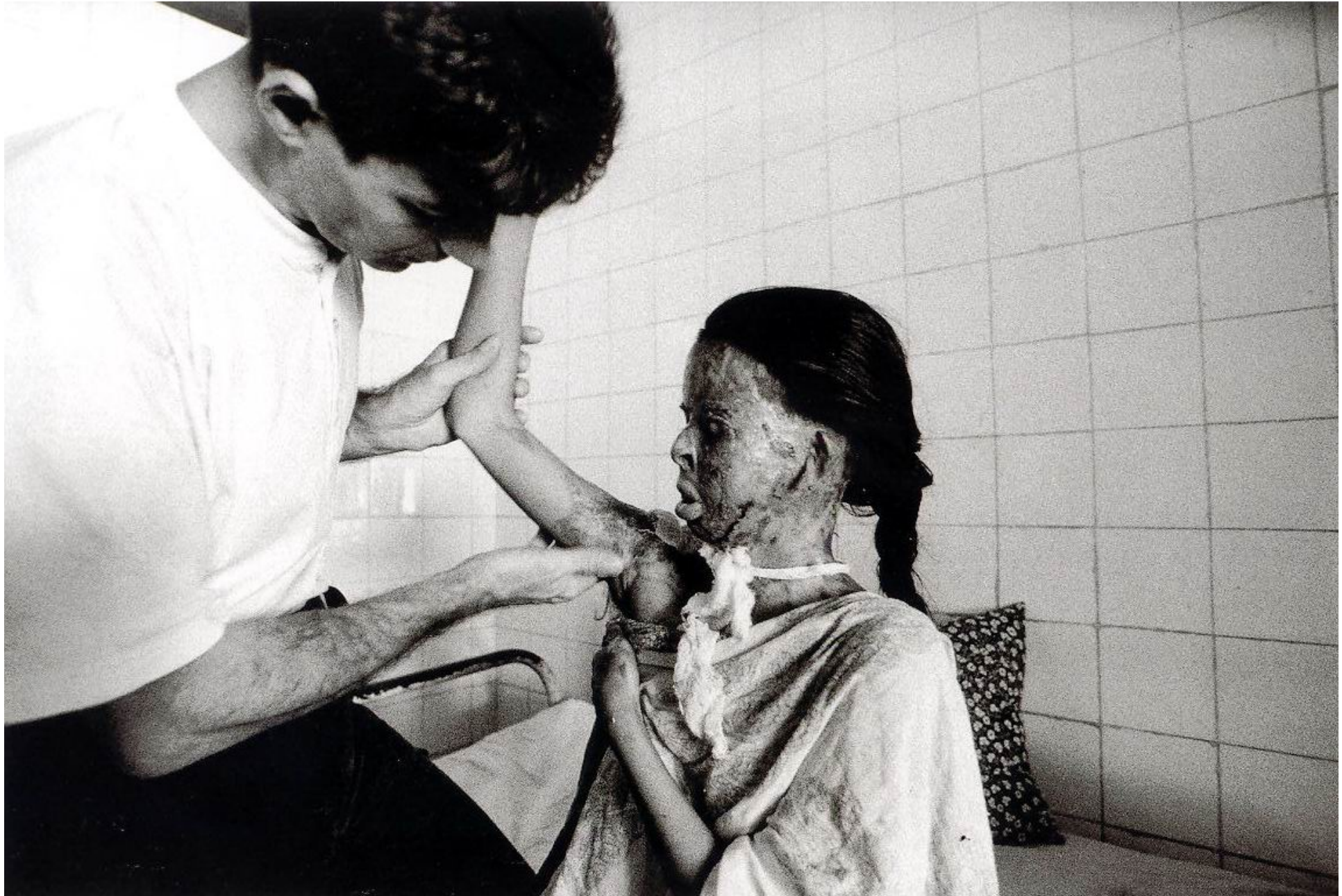di Ugo Panella
testo
di Renata Pisu





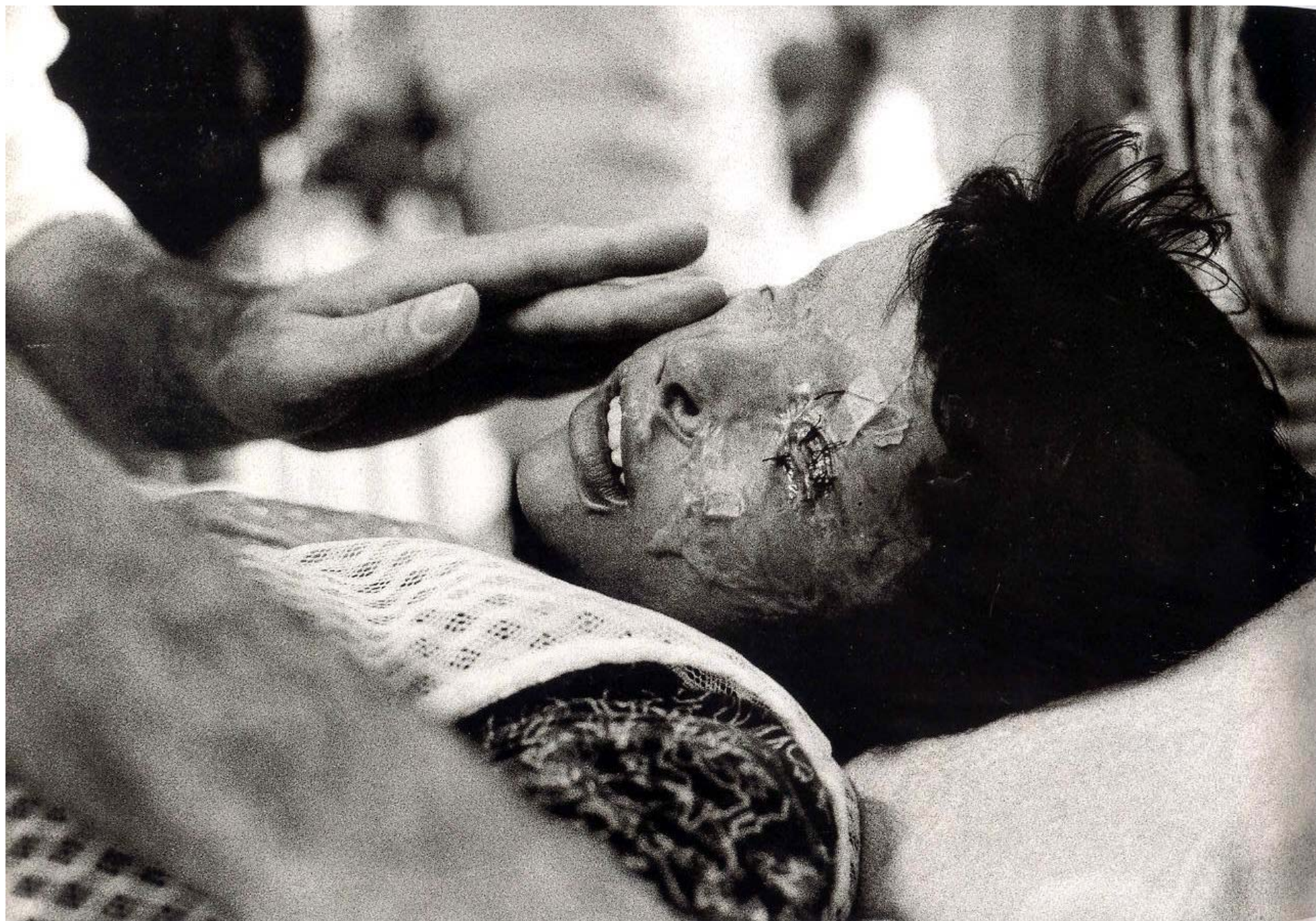A young woman holding a picture showing her before the acid attack

The physiotherapist visiting a young patient

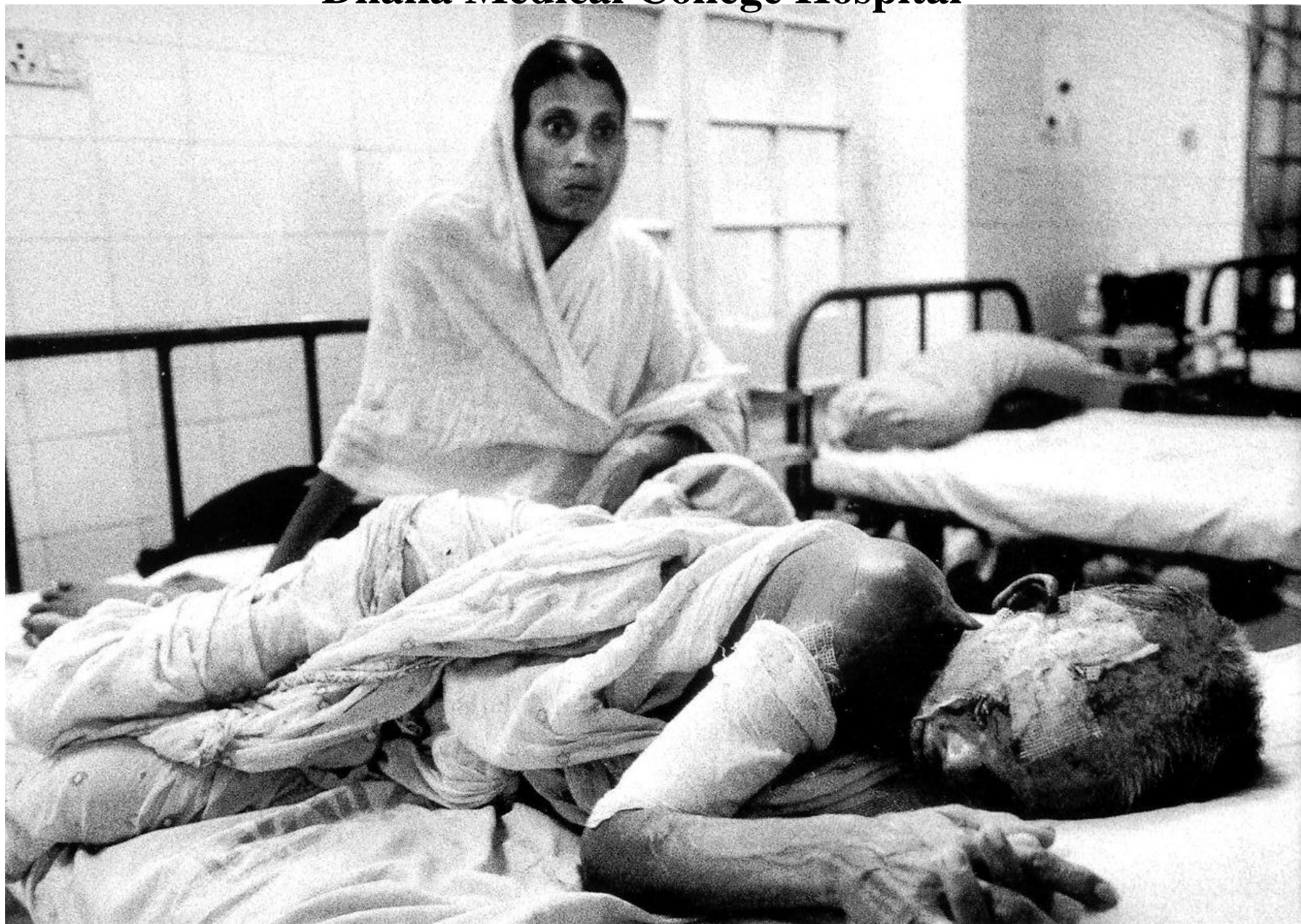


A patient seriously injured on the face

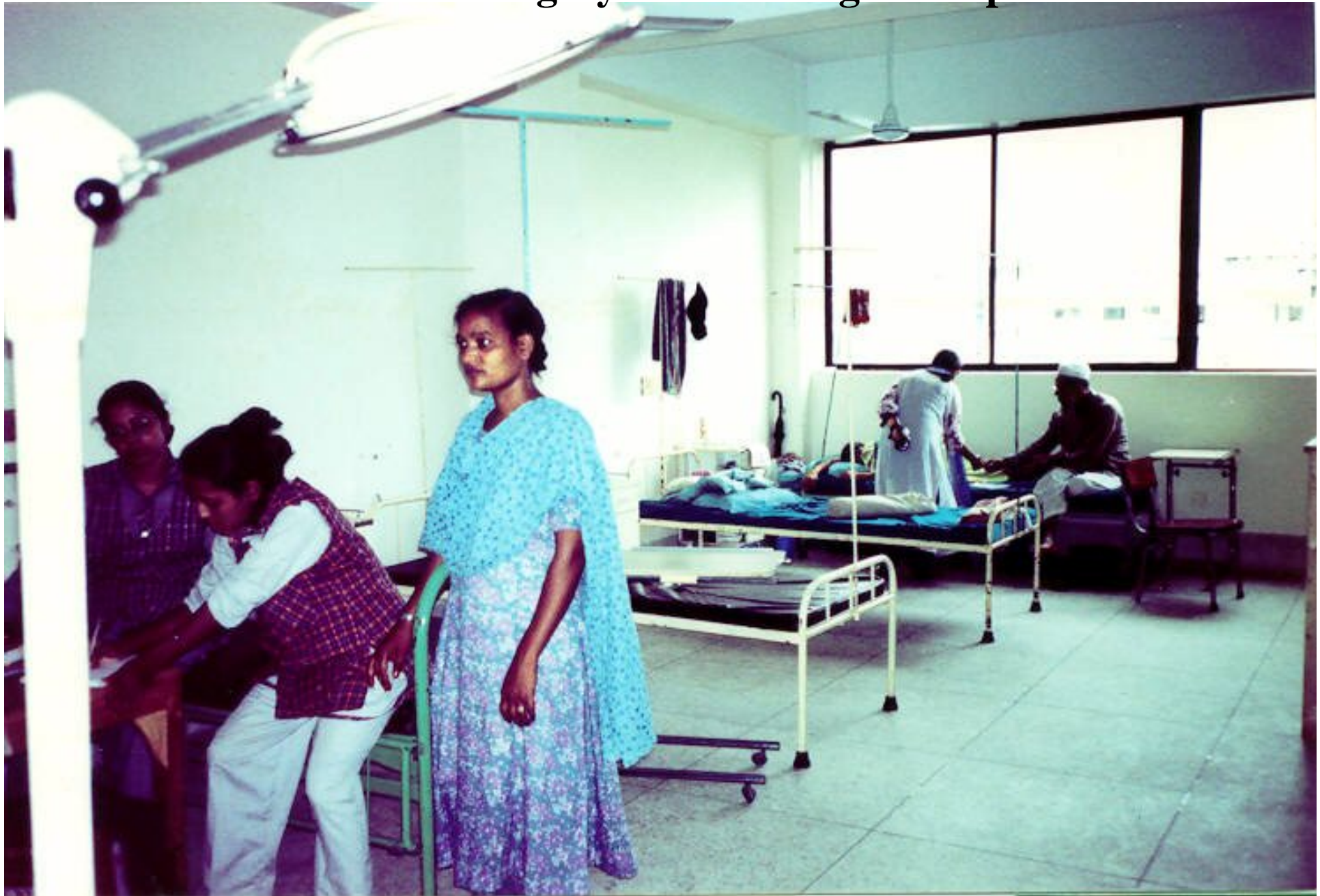


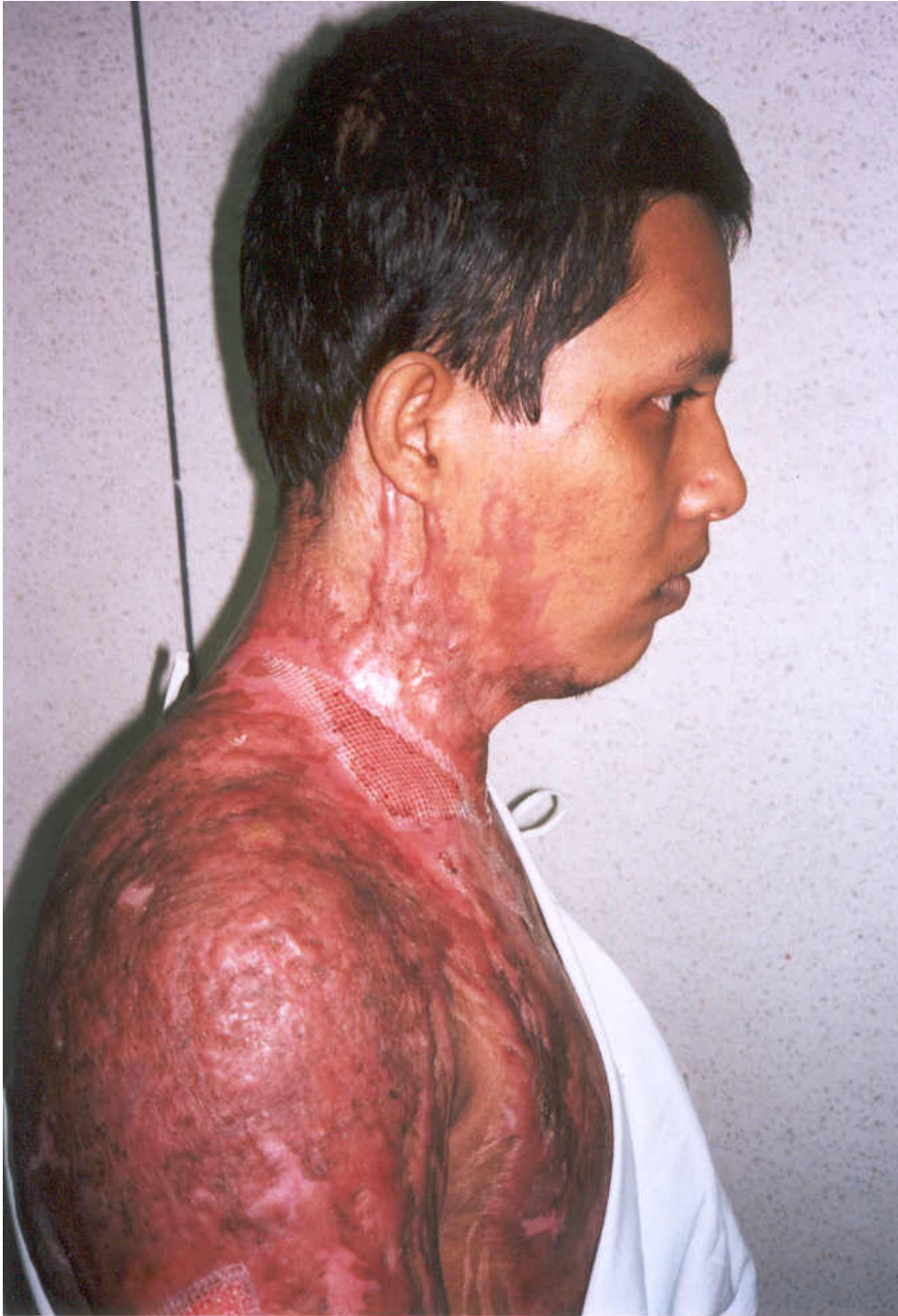
Dhaka Medical College Hospital



Dhaka.Plastic Surgery ward at Nagar Hospital



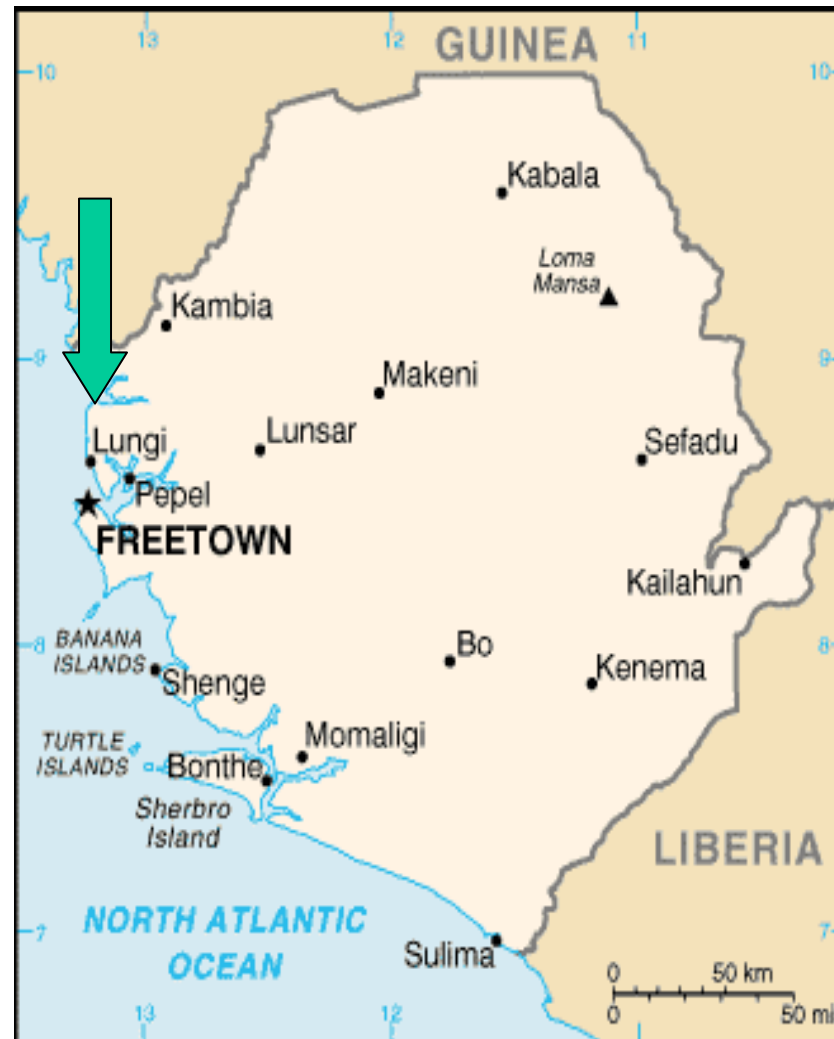
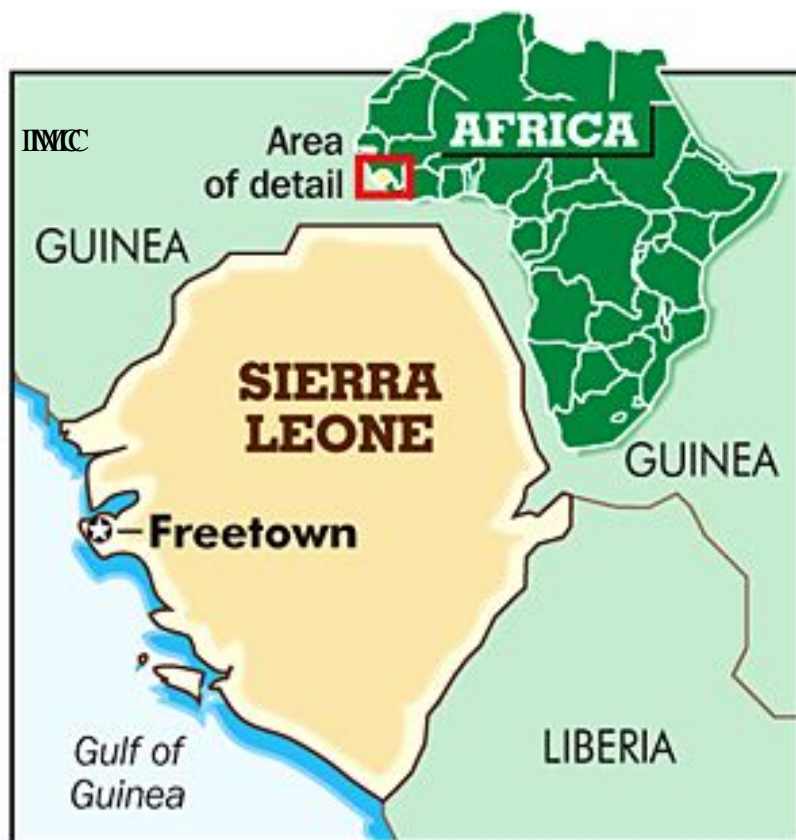
Acid Burn progressing to neck contracture

Dhaka. Old city



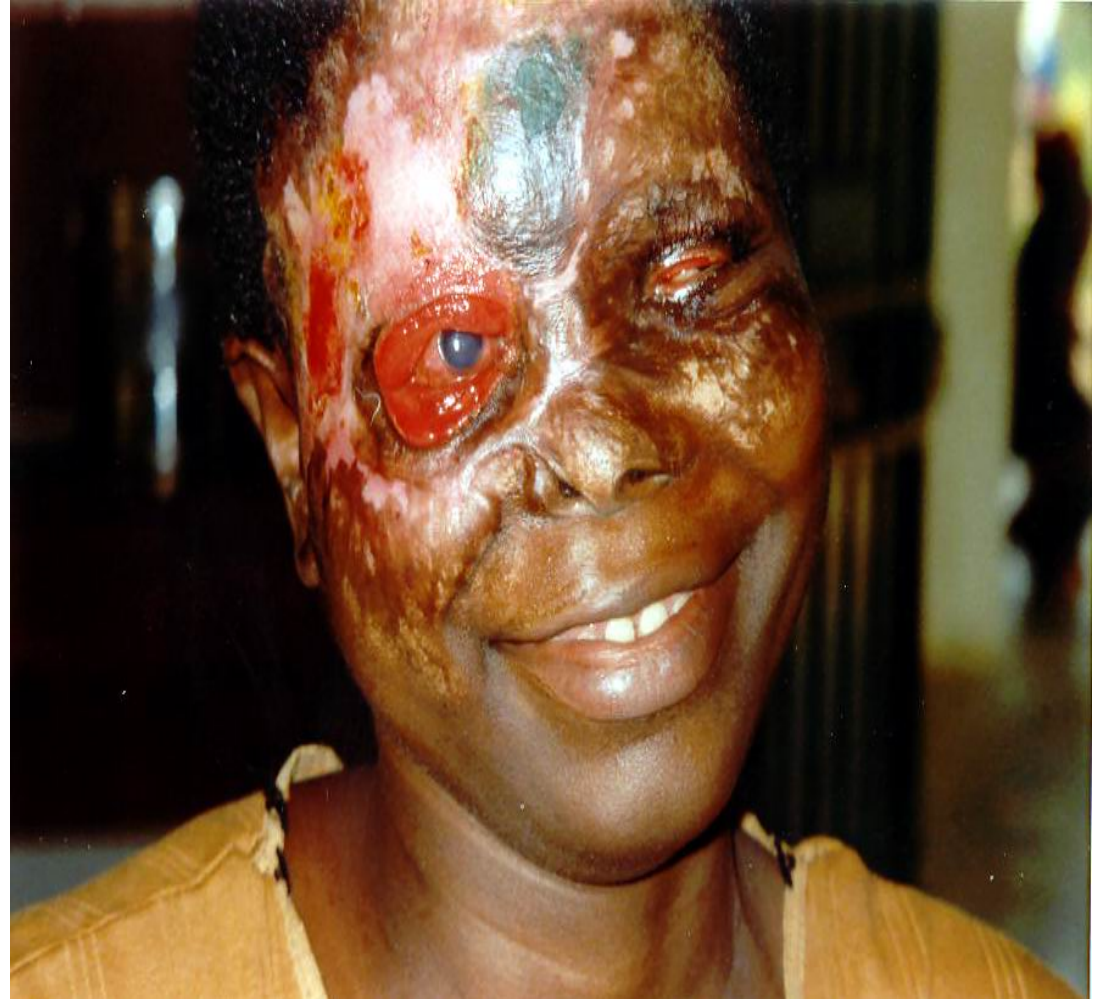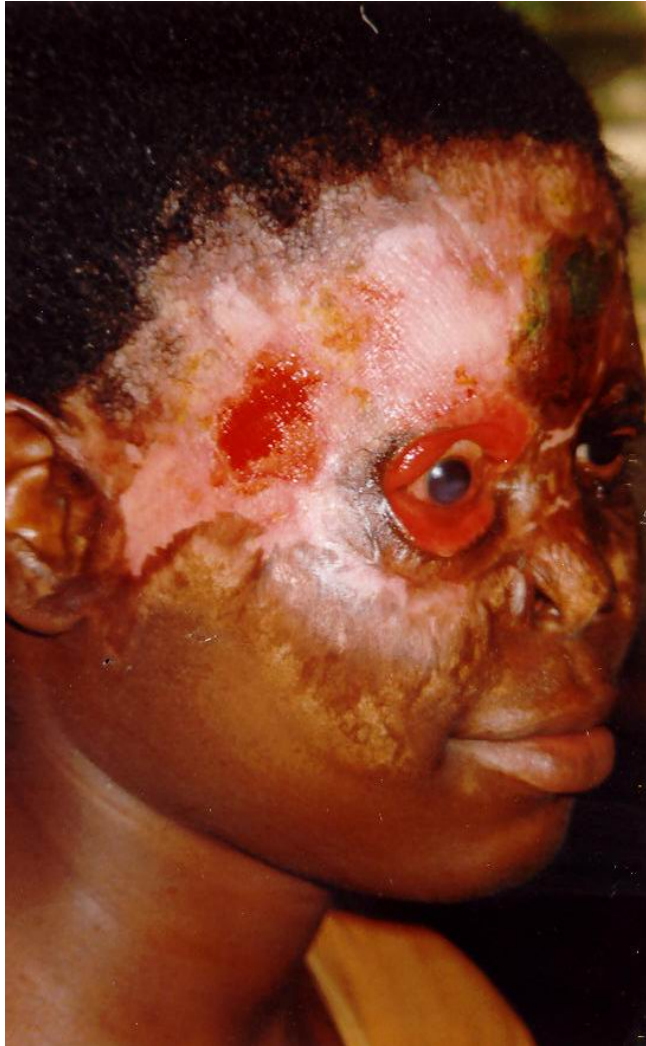Plastic Surgery Project in Sierra Leone- Lungi Hospital-Freetown

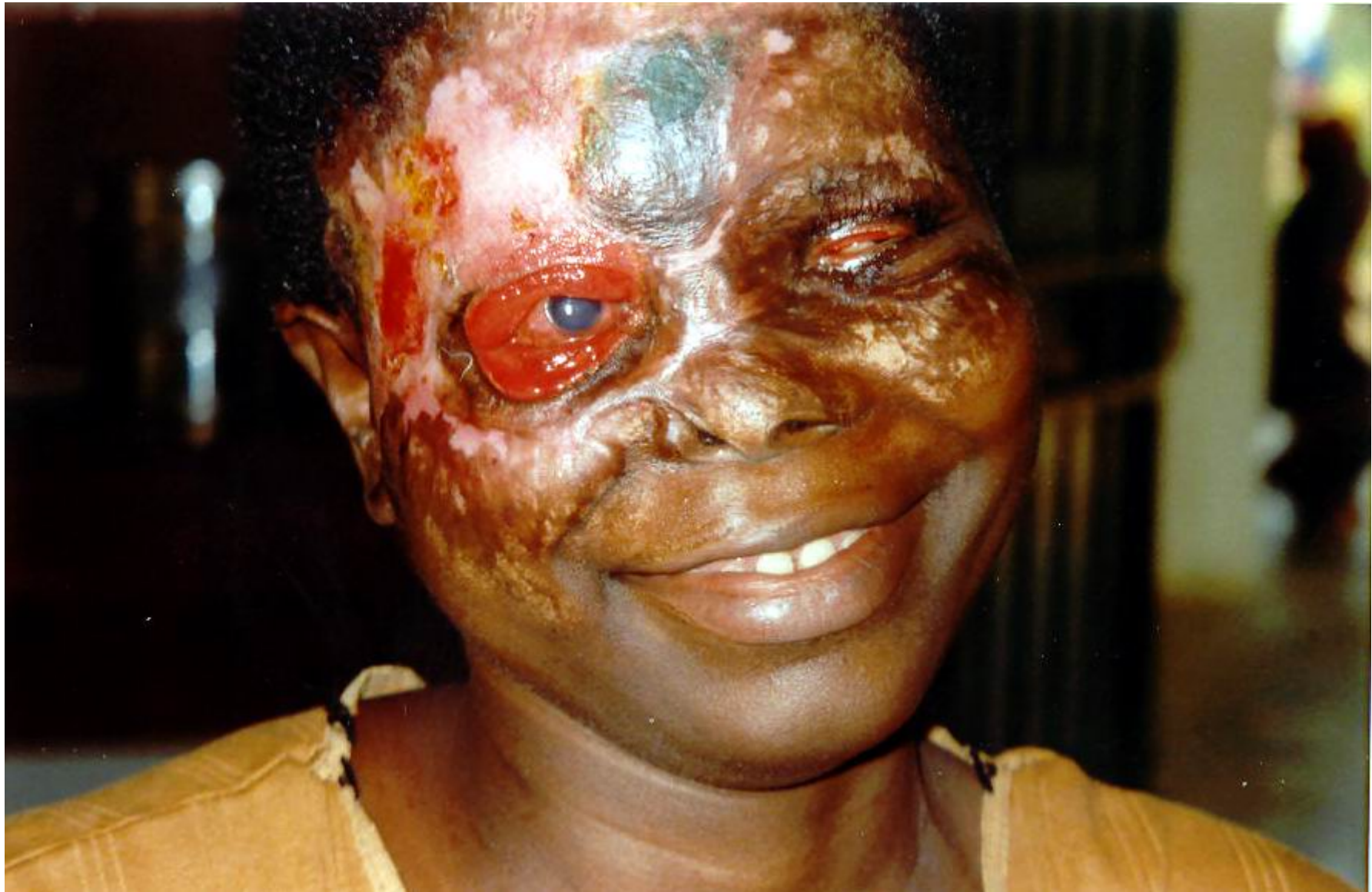

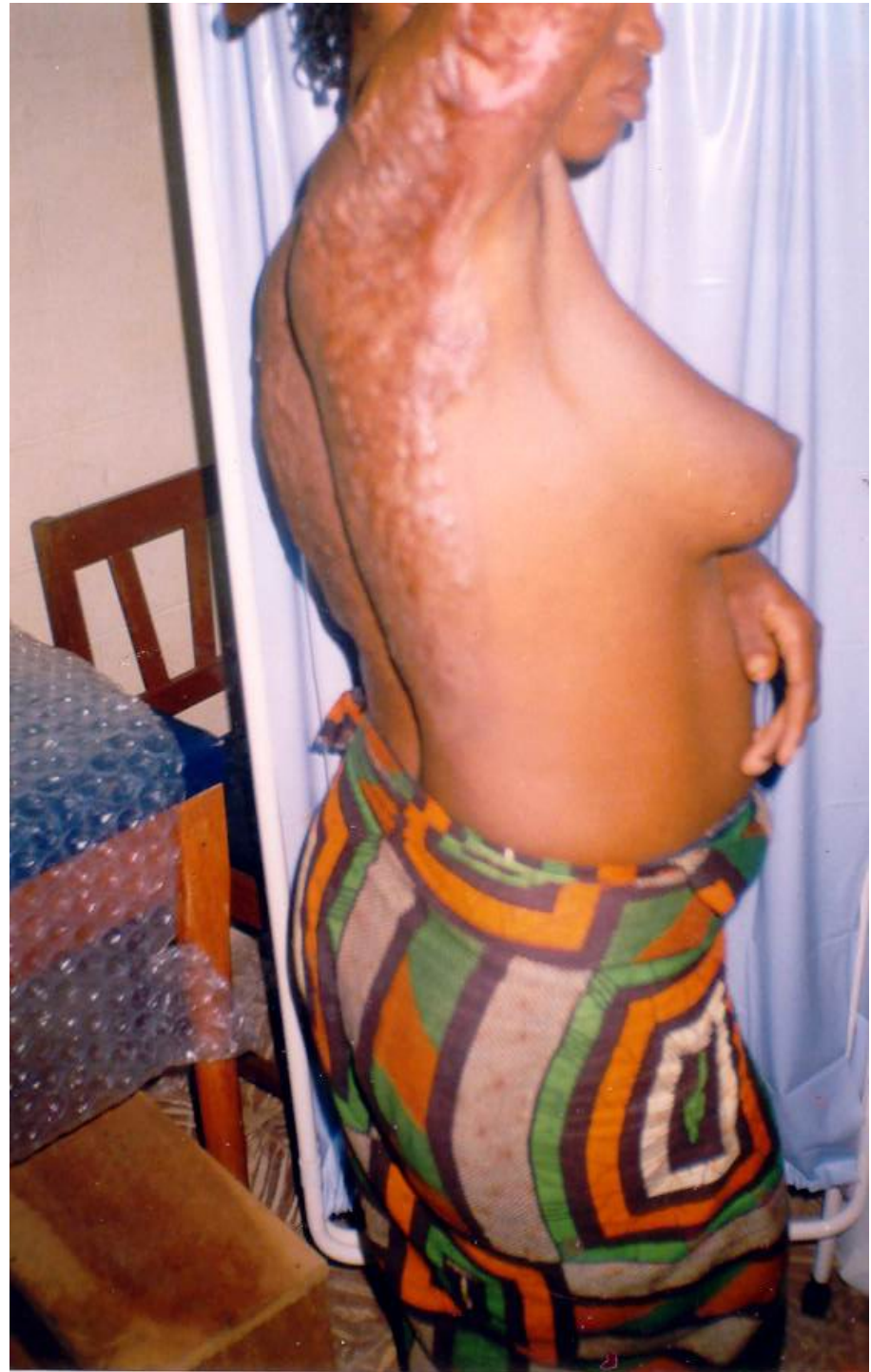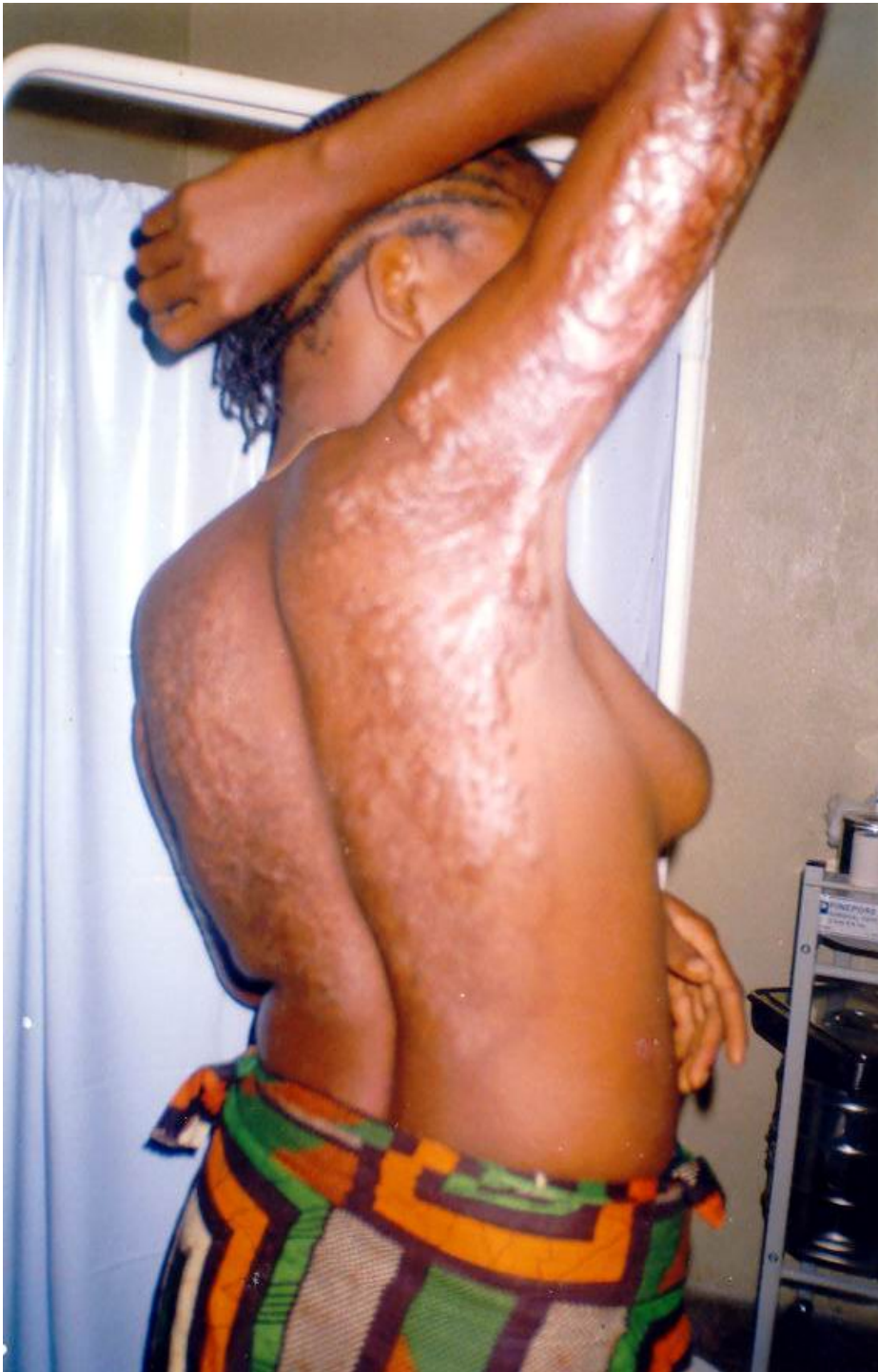Plastic surgery ward in Sierra Leone



Burn Contractures in Sierra Leone







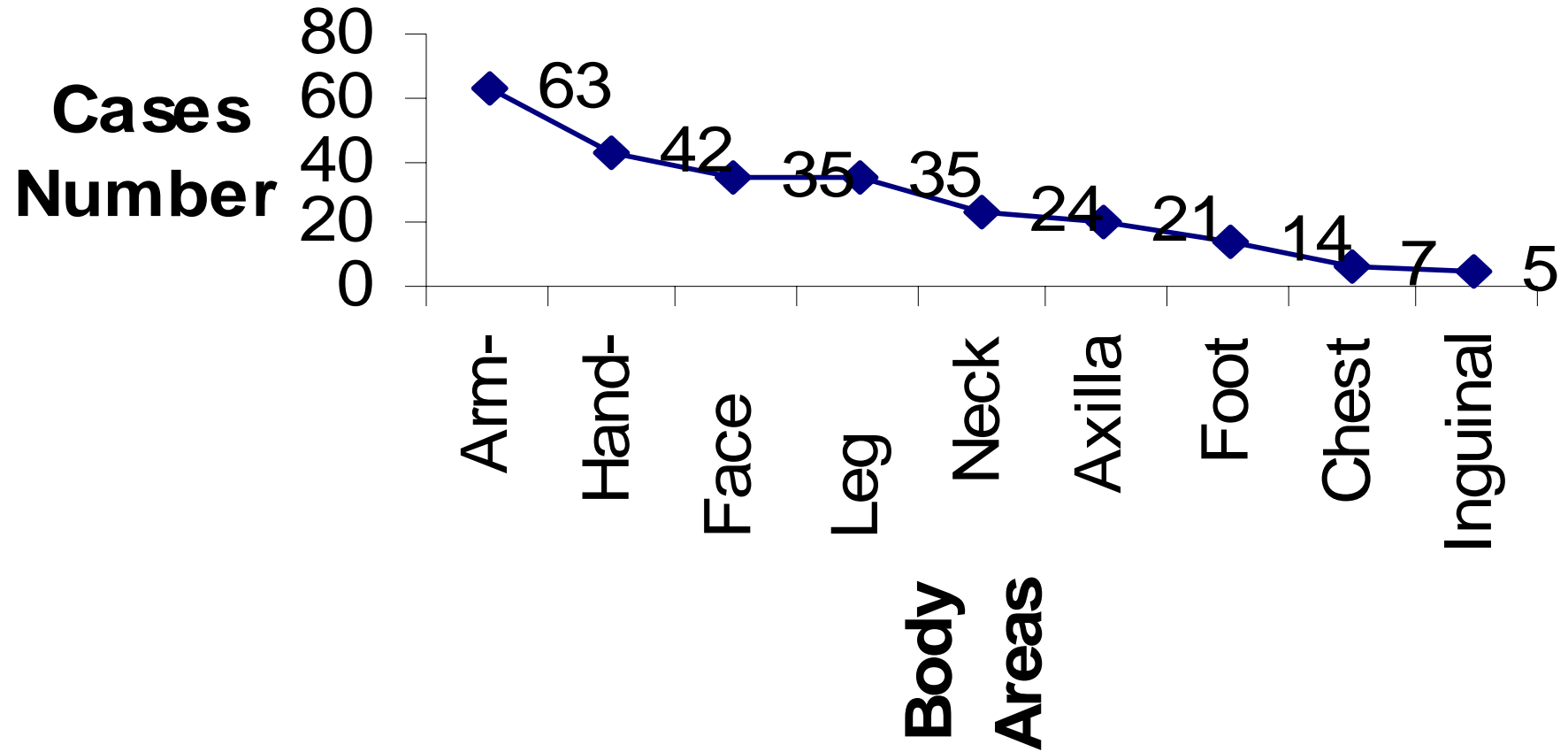
PLASTIC SURGERY PERFORMED

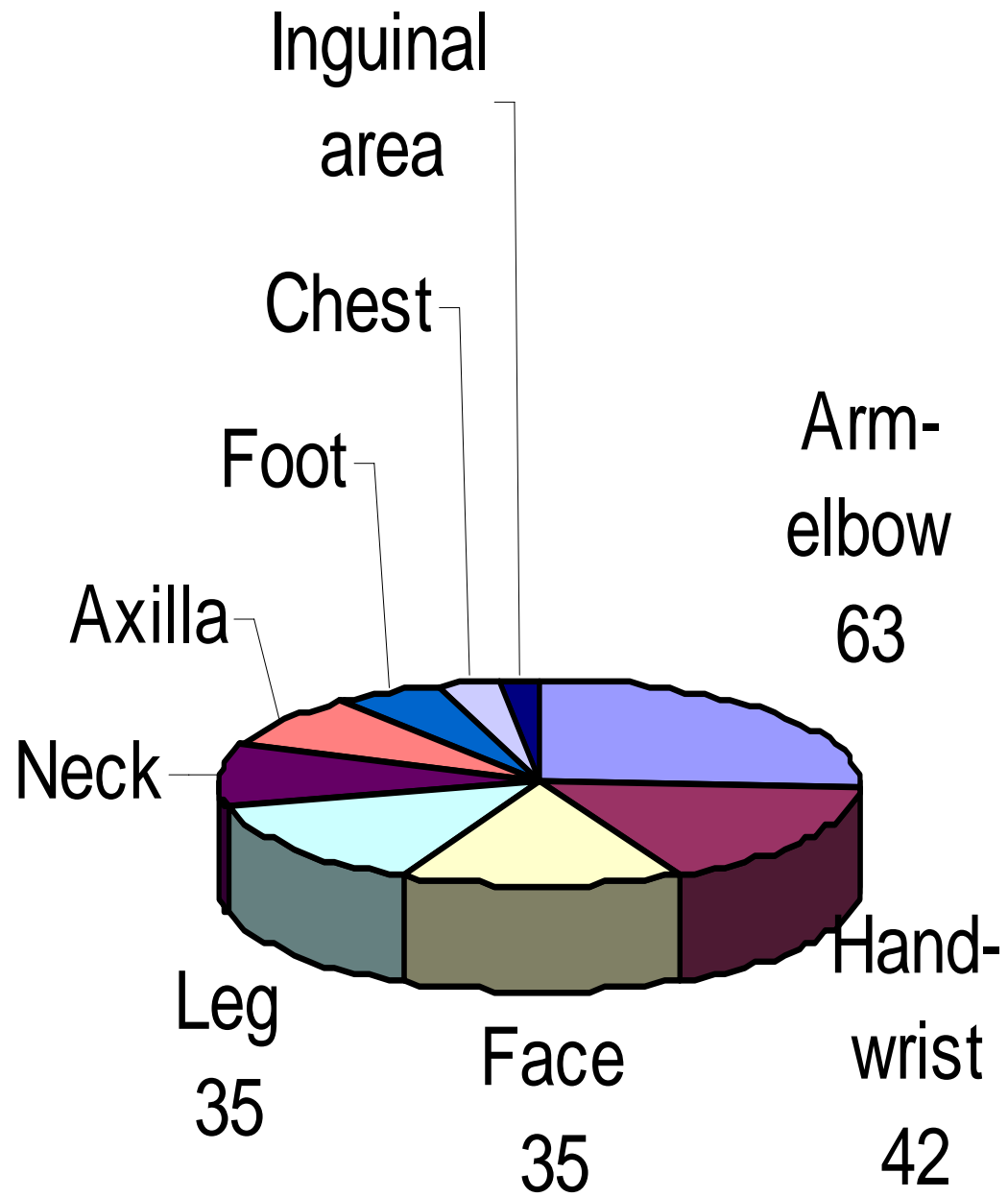
Country	Total cases	Contracture Surgery
Mozambique-1999	100	35
Bangladesh-2000-2001	240	115
Sierra Leone-2001-20002	135	80
Kenya-2003	16	16
<hr/>		
AMOUNT	491	246

Total Cases 246

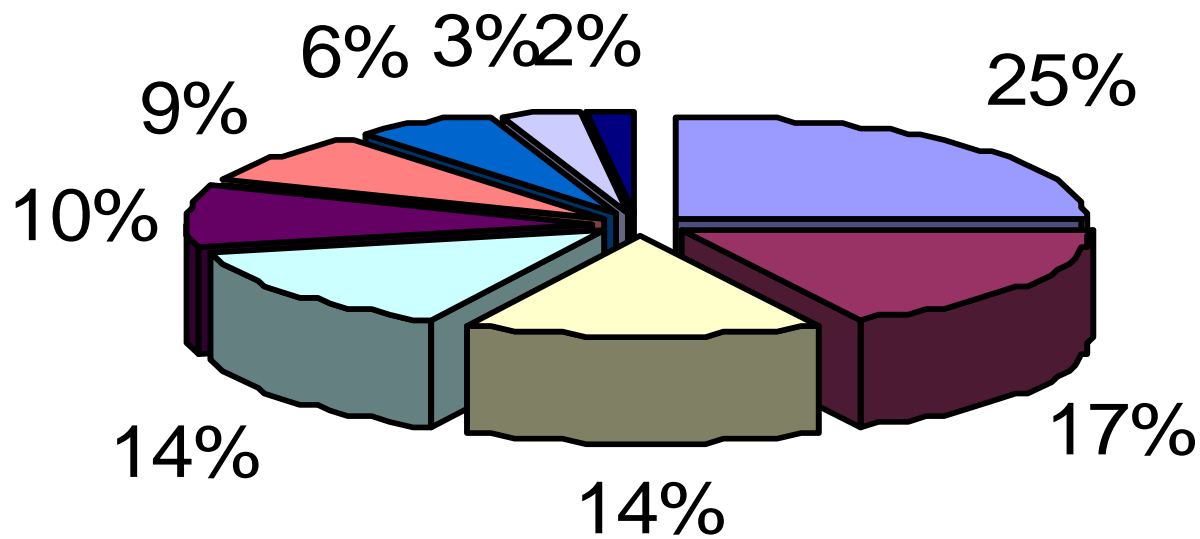
Contractures in body areas

Series 1





Arm-elbow	63	Hand-wrist	42
Face	35	Leg	35
Neck	24	Axilla	21
Foot	14	Chest	7
Inguinal area	5		

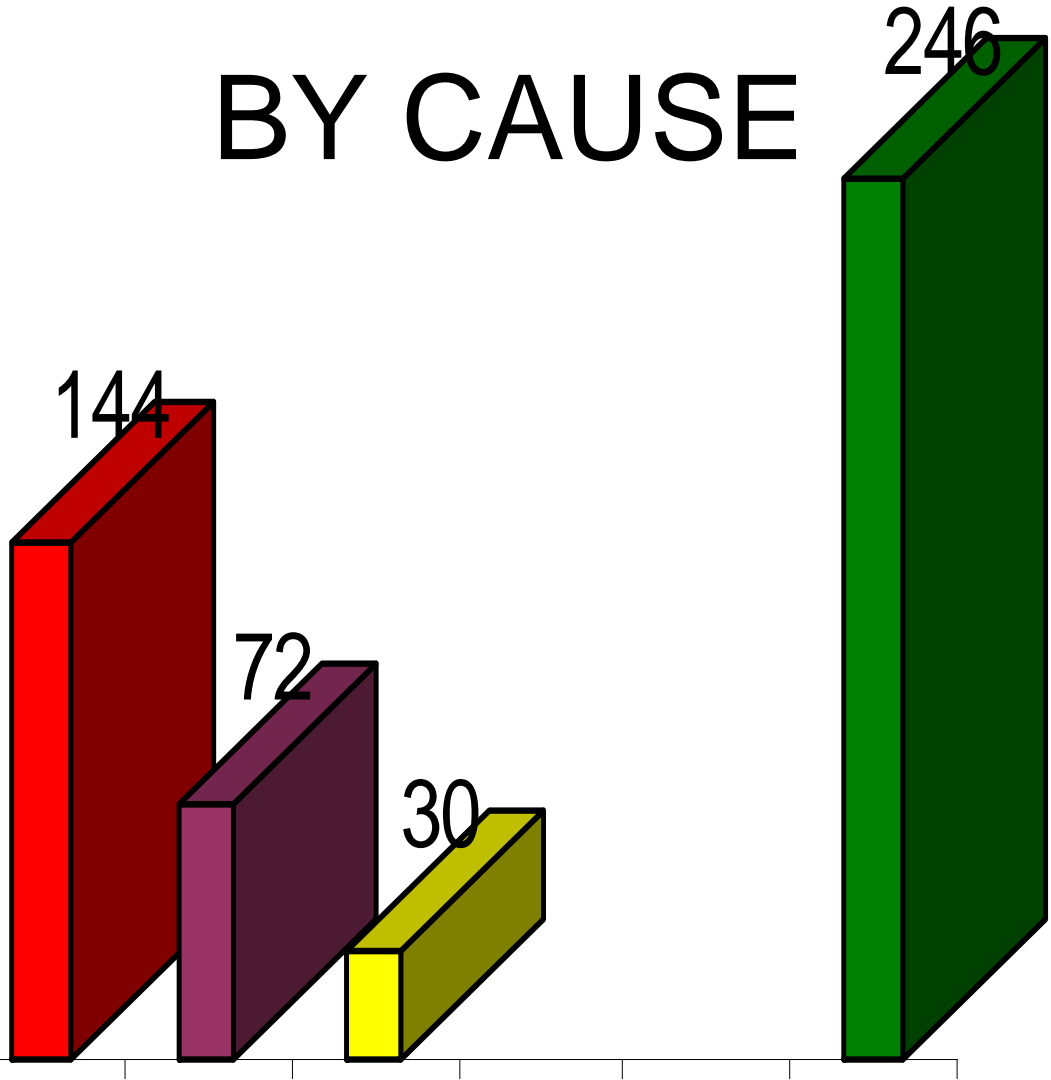


Total Cases 246

BY CAUSE

250
200
150
100
50
0


fire acid boil.liquid TOTAL



- Series1
- Series2
- Series3

BY AGE

cases number



0-10

10 to 20

20 to 30

30 to 40

over 40

Total cases

age

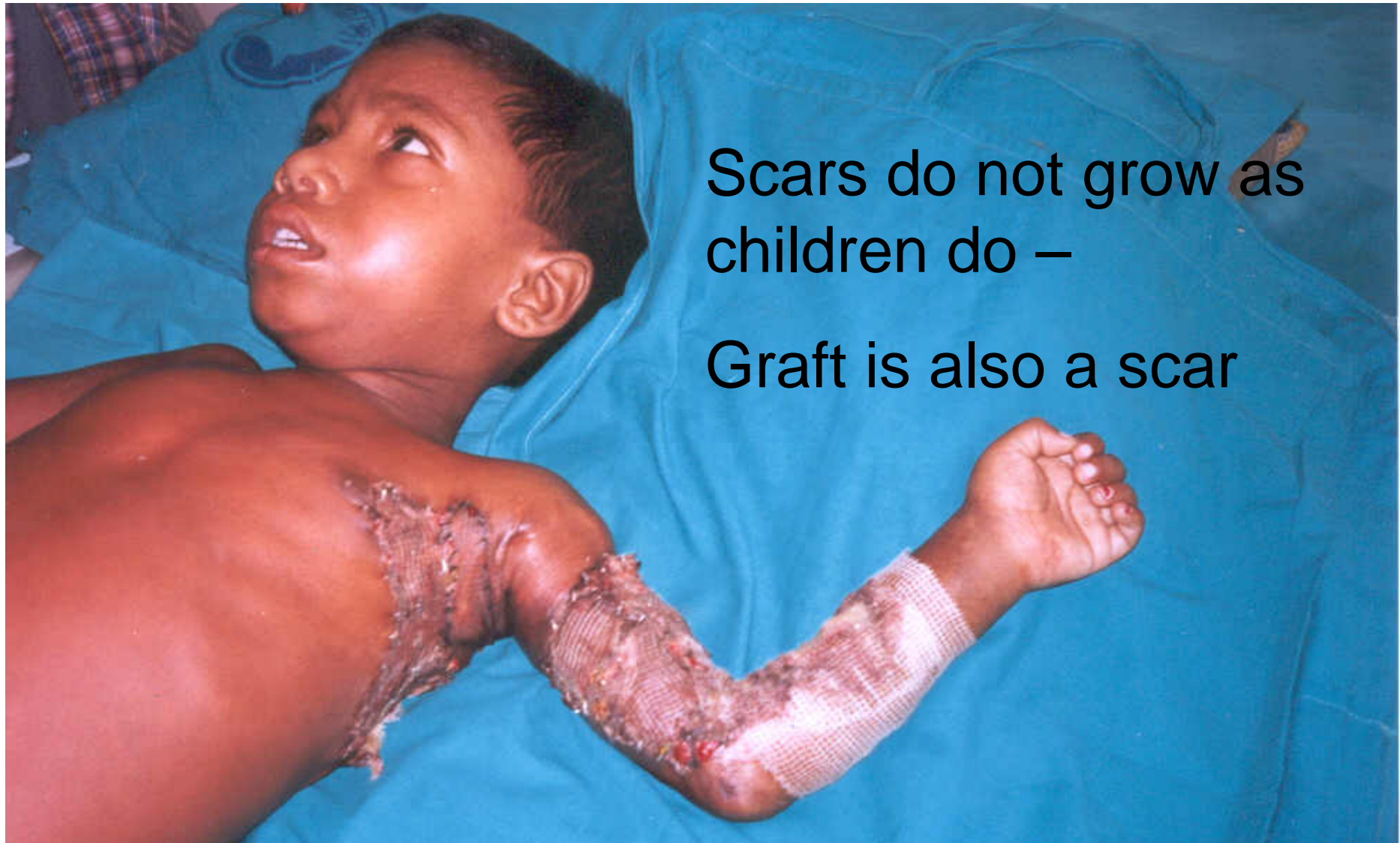We gave particular attention to burn contracture surgery, which represents the most frequent required intervention on women and children.

We have taken into consideration 246 cases of contractures.

Considering those two above mentioned categories we developed with positive results some techniques, according to our experience and some important considerations.

Skin grafts tend to contract, thus hampering the normal child's growth during the following years.

Burn reconstruction in children



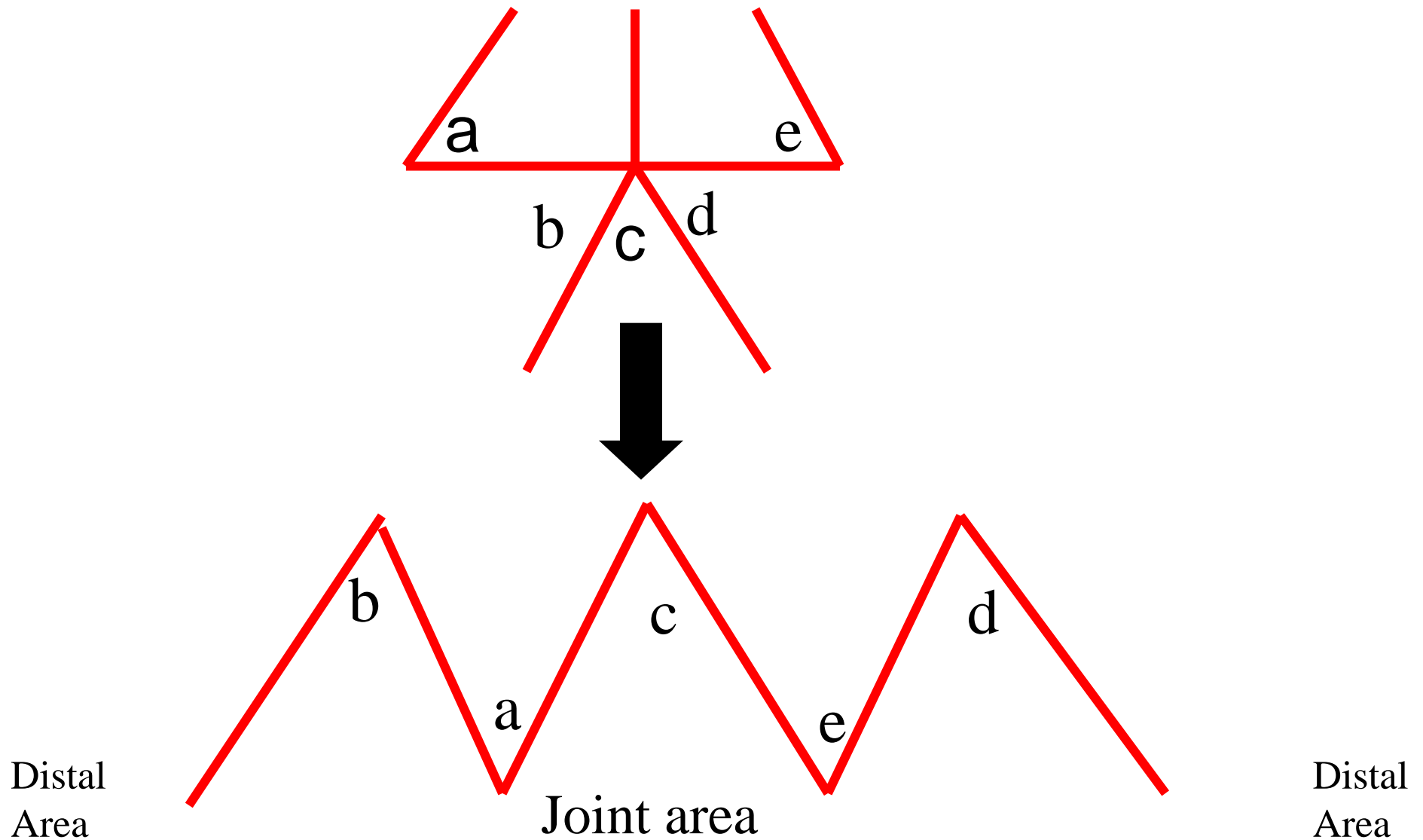
Scars do not grow as children do –
Graft is also a scar

Arm adhesion to the chest

That's why especially in joints areas we prefer the transposition of local flaps. These sometimes can be complex but they are reliable for what concerning blood supplies and their integration in child's growth.

In arm and leg severe burn contractures we were using a five limbs or more complex transposition flaps.

Five limb transposition flap



Techniques available for burn reconstruction

1) Without deficiency of tissue

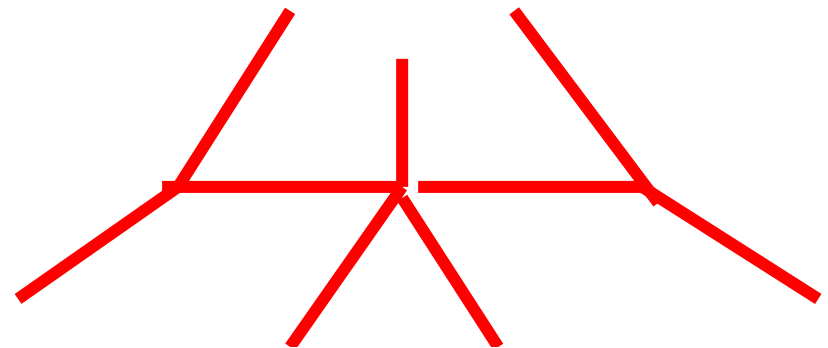
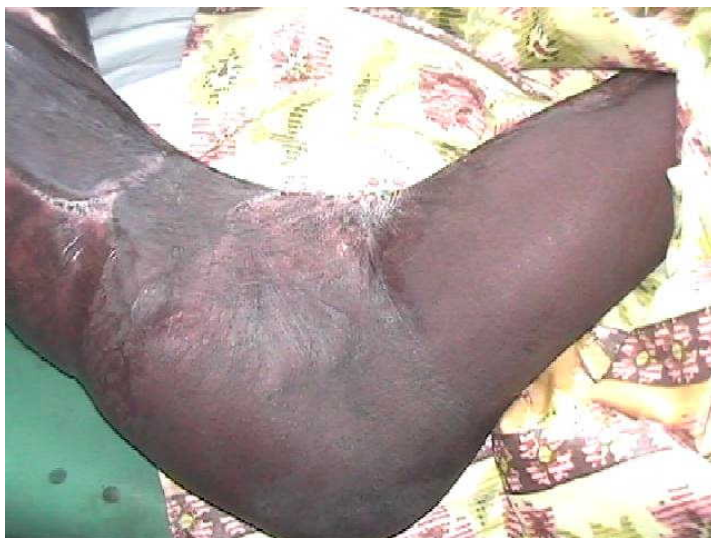- a) Excision and primary closure
- b) Z- plasty

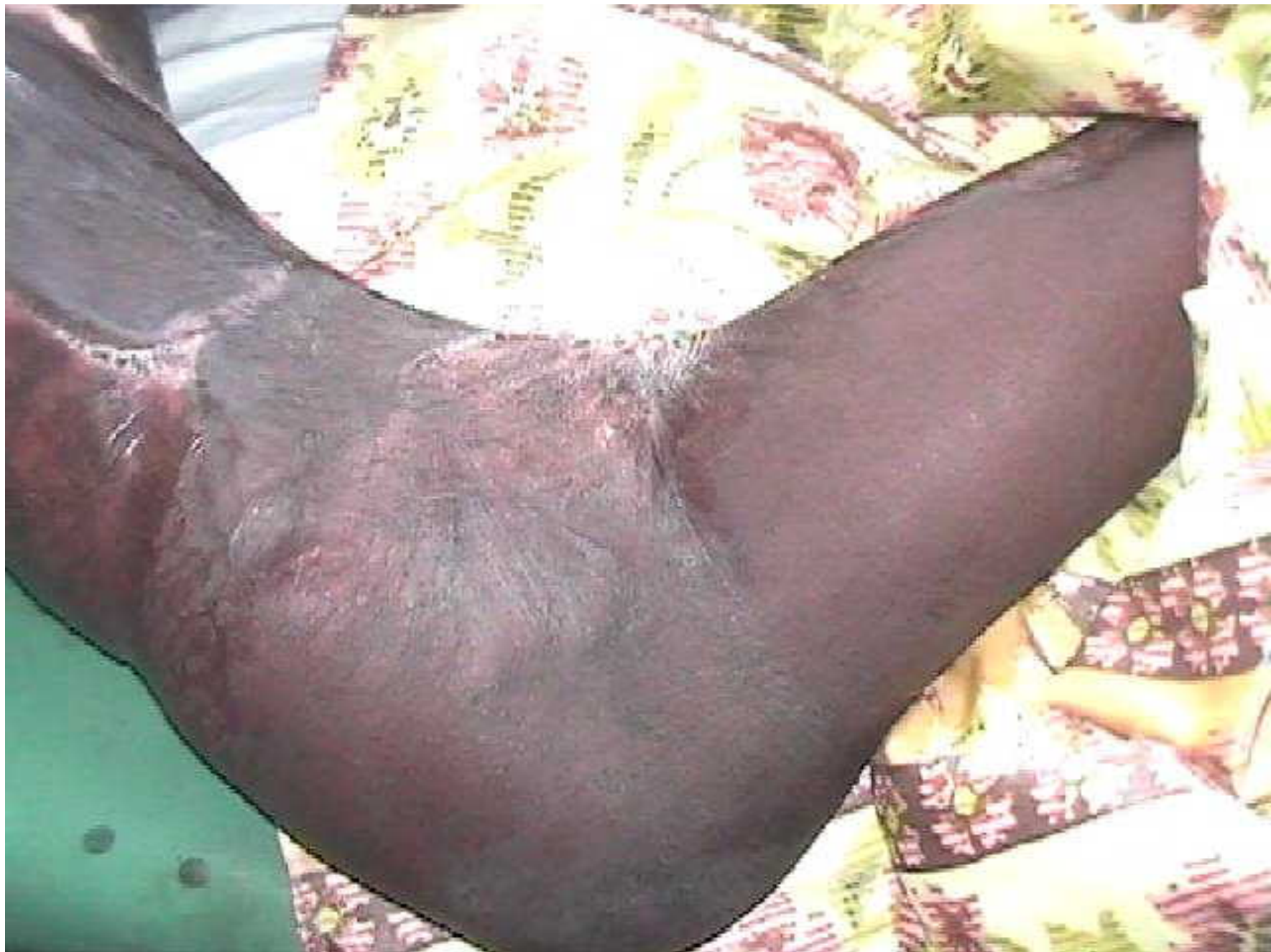2) With deficiency of tissue

- a) Skin graft
- b) Transposition flaps
- c) Axial and random flaps
- d) Myocutaneous flaps
- e) Tissue expansion
- f) Free flaps

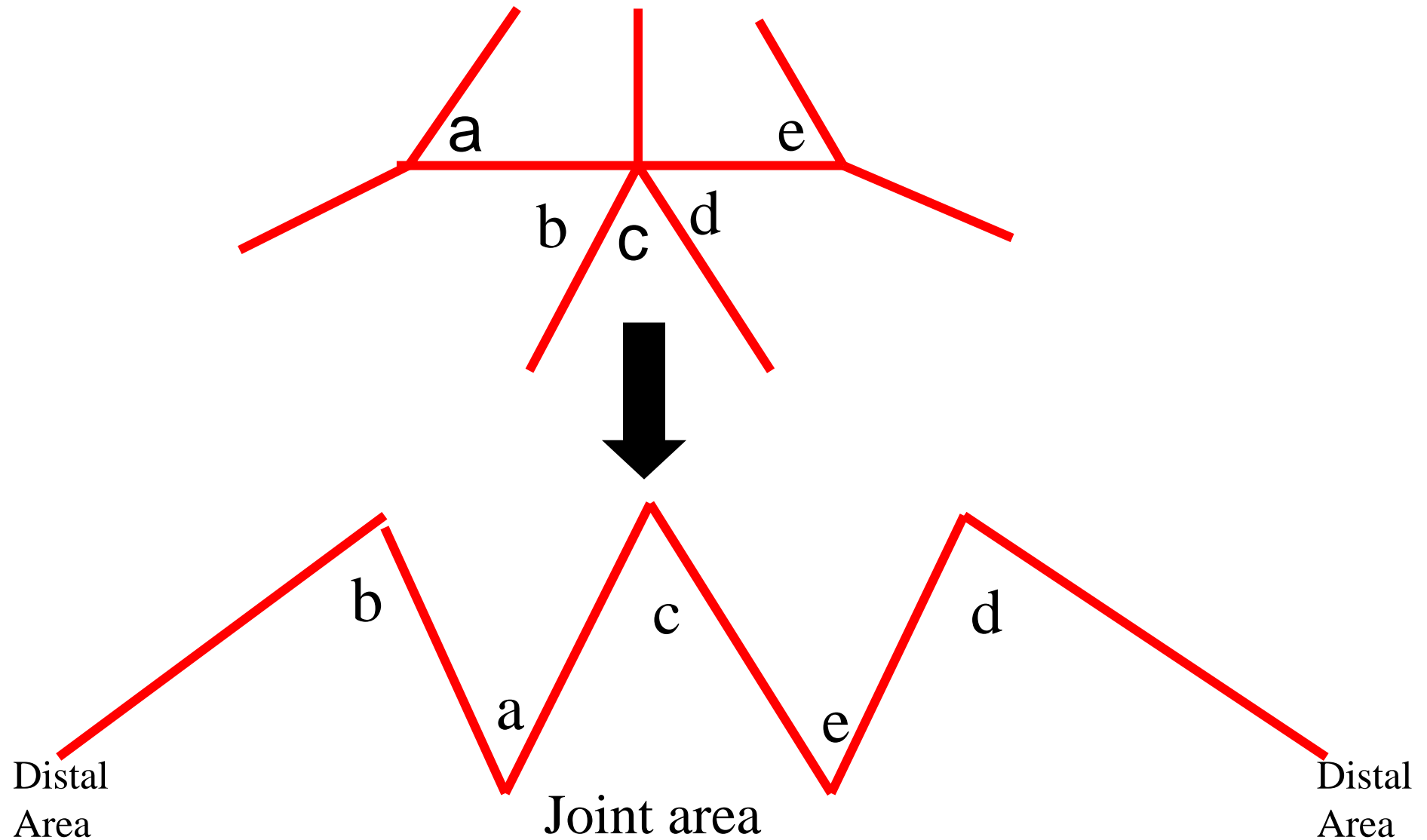
When more extensive contractures were present we made adjunctive flaps or thin grafts in distal areas, as in the following cases of severe contractures. We minimize the blood loss by tissues infiltration (2mgr adrenaline in 1000 cc saline)

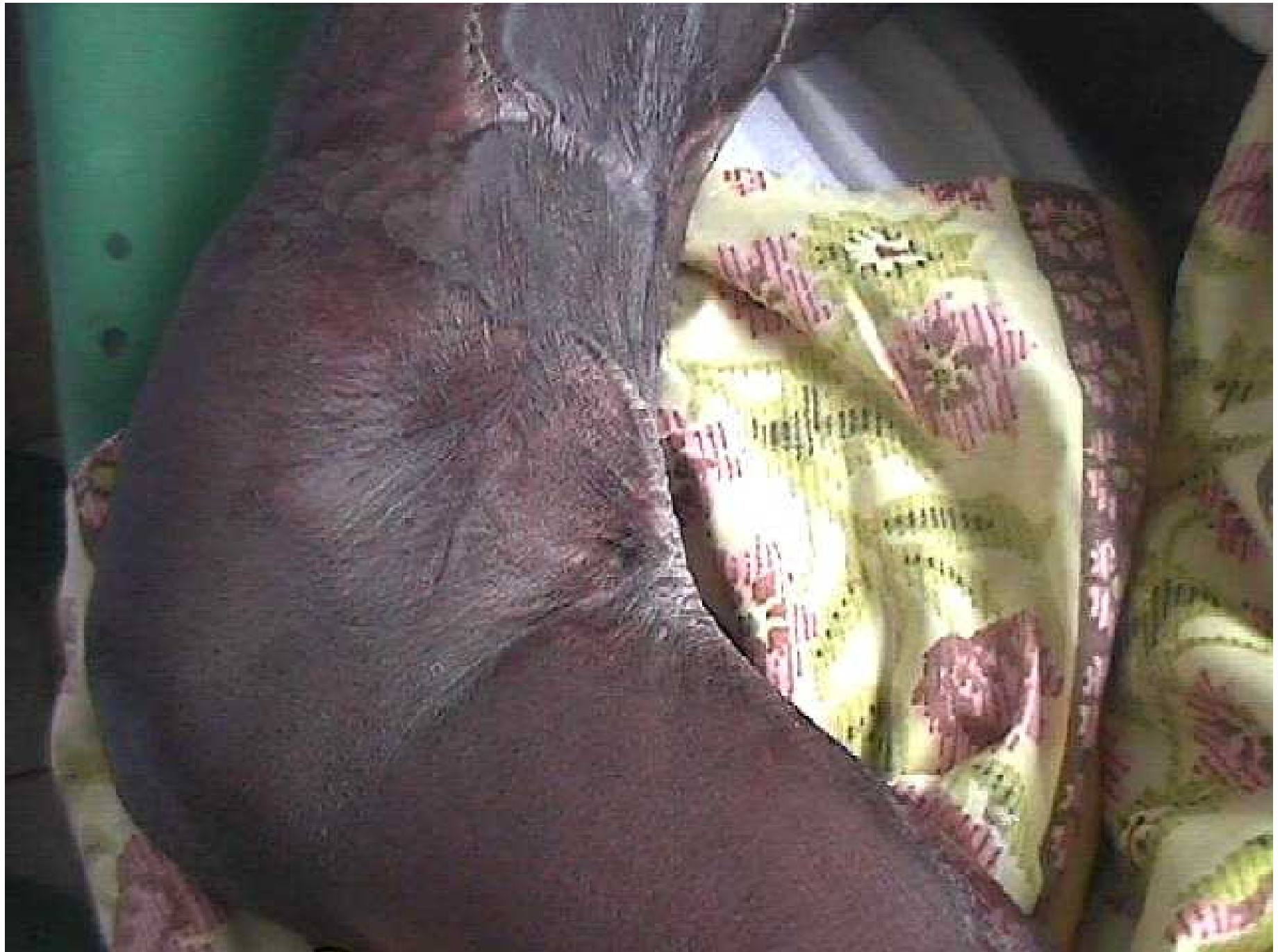The flaps have to be tailored on patient's needs. In this case of severe leg contracture we made a seven limbs flap, very useful when there is not much good skin laterally in joints and in distal areas. As you can see the flap is composed by three Y advancing to V and by two Z

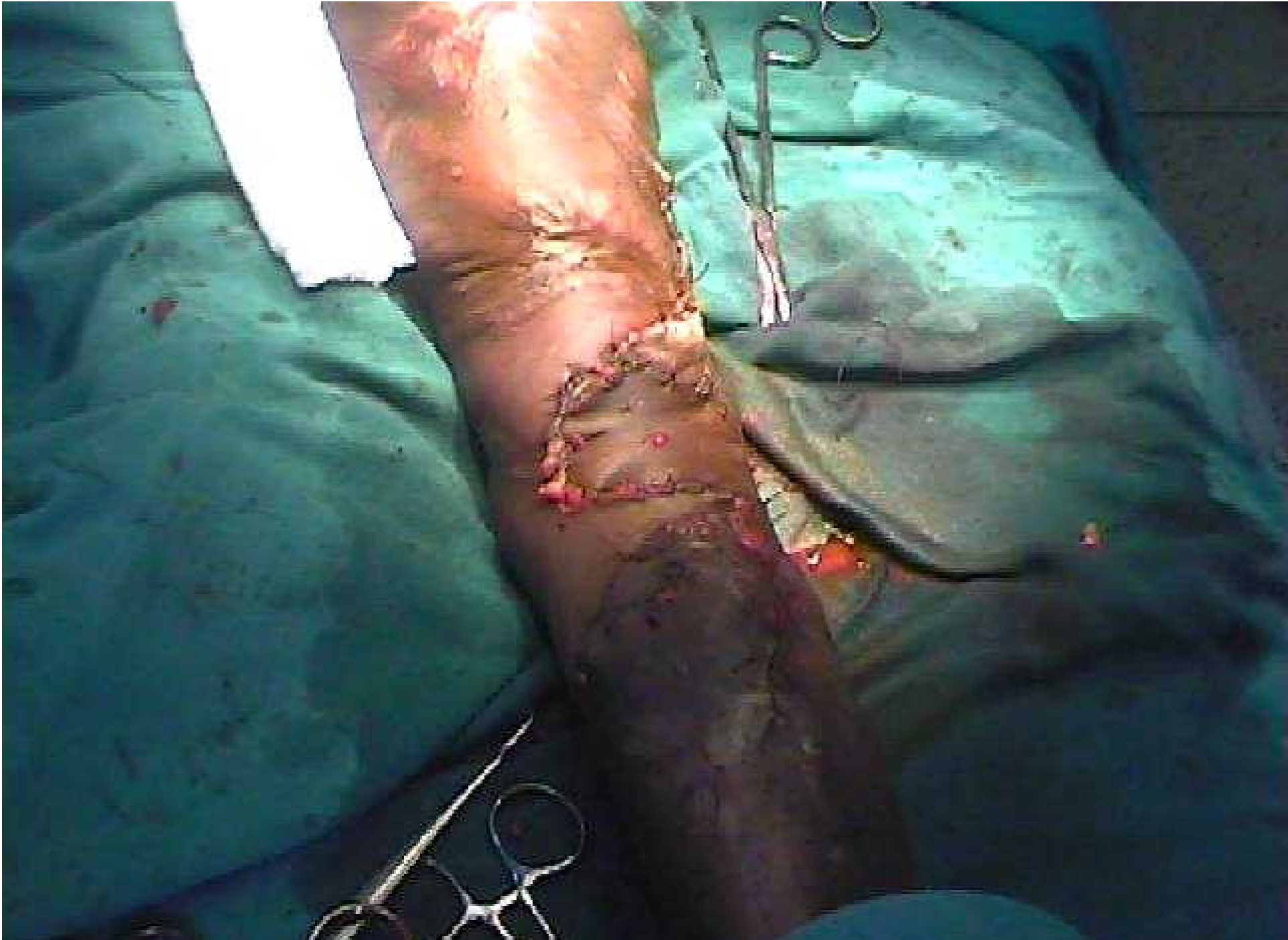


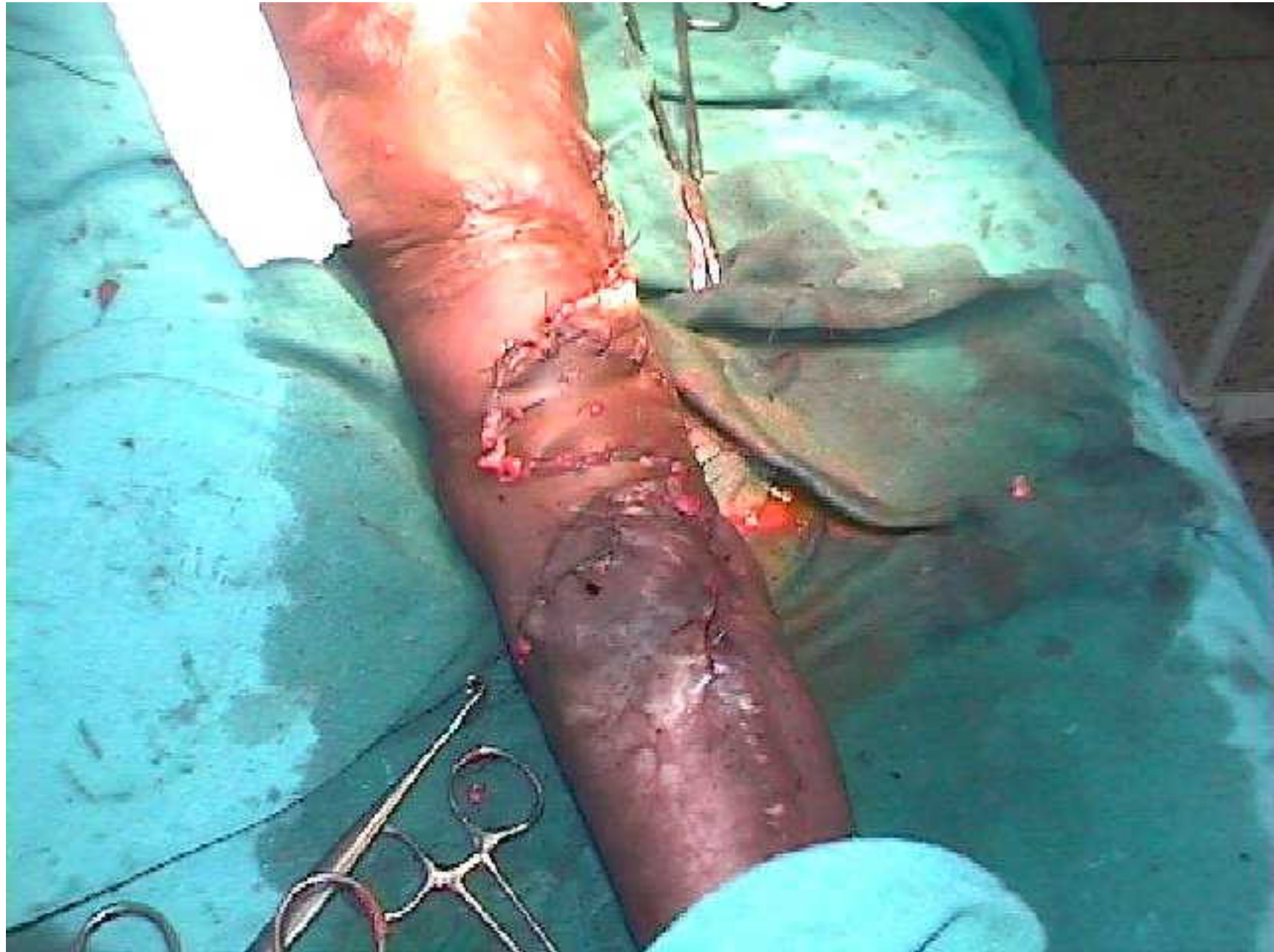
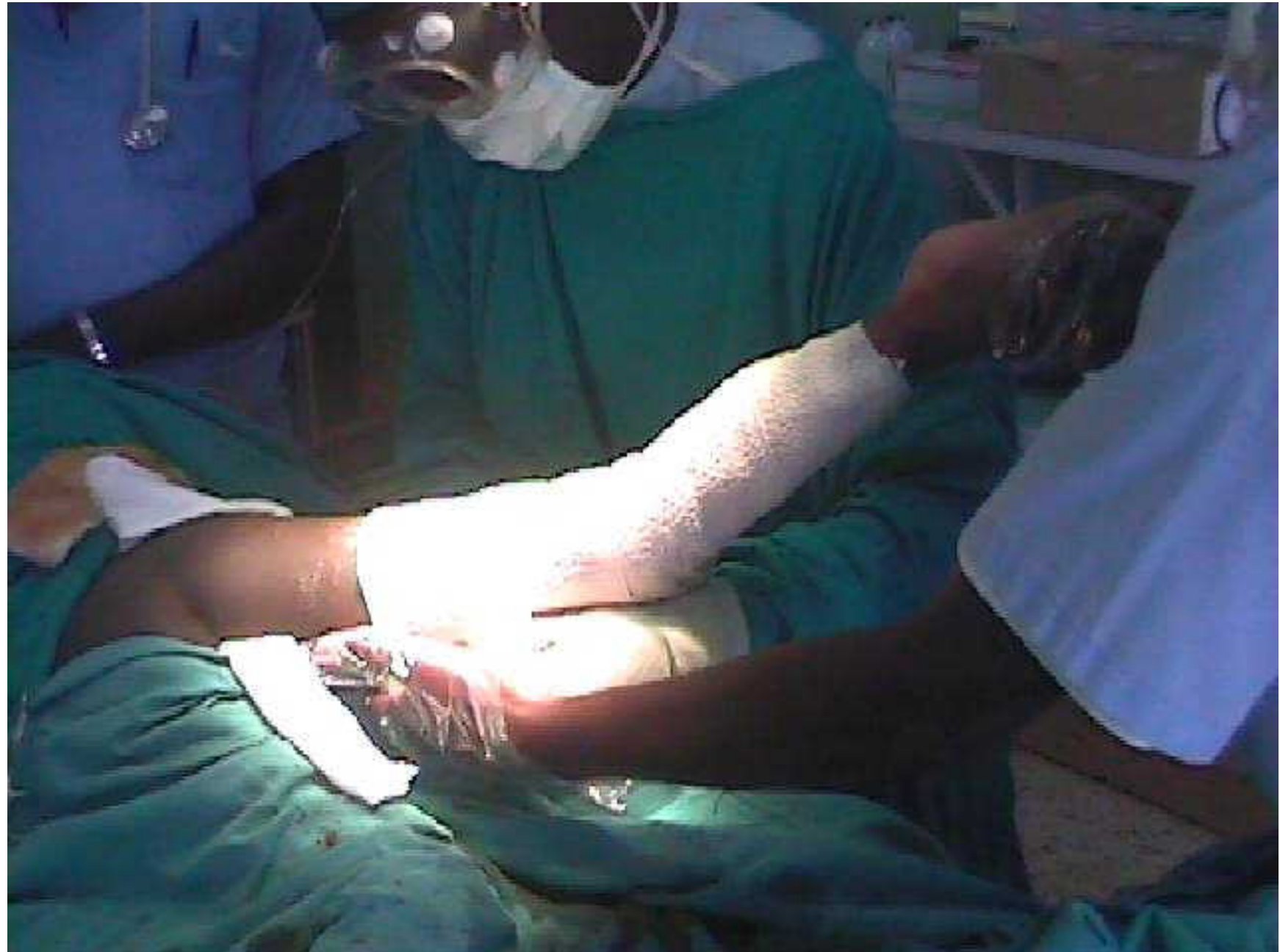Seven limbs transposition flap





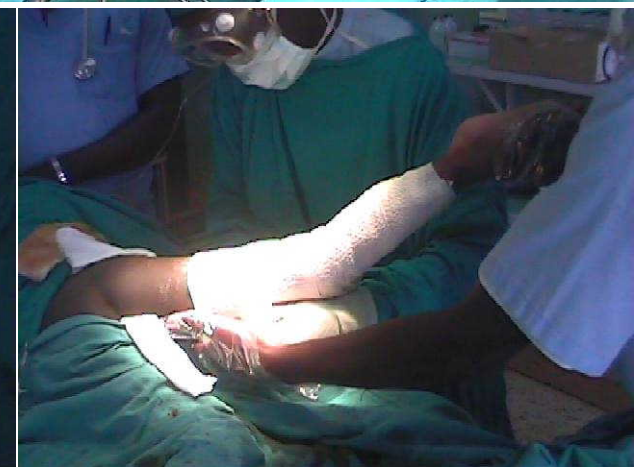
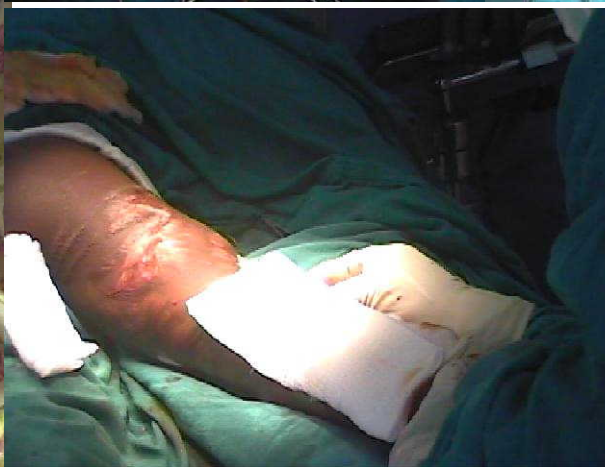
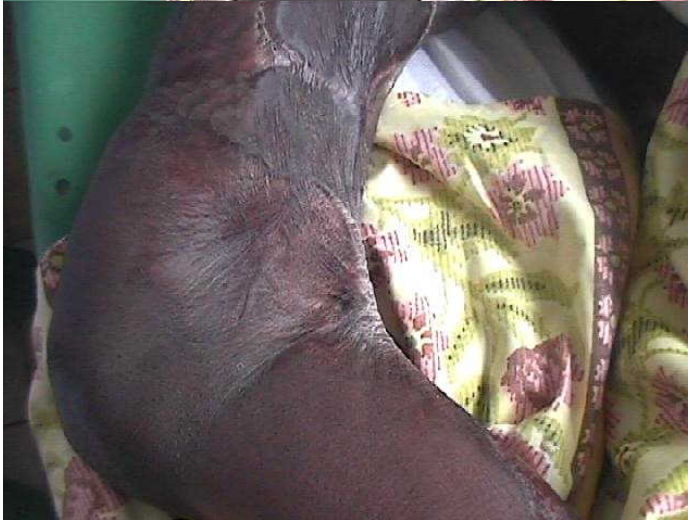
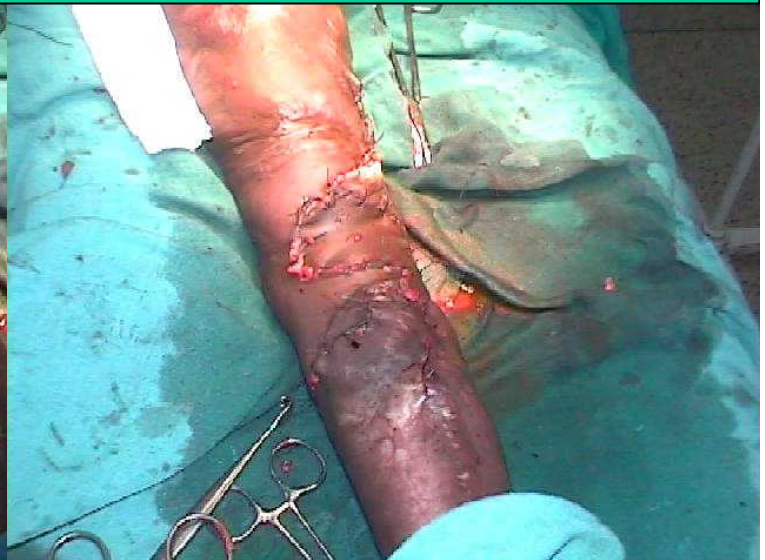
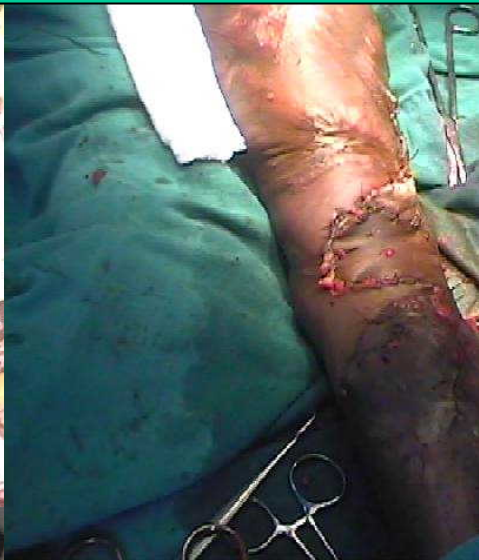
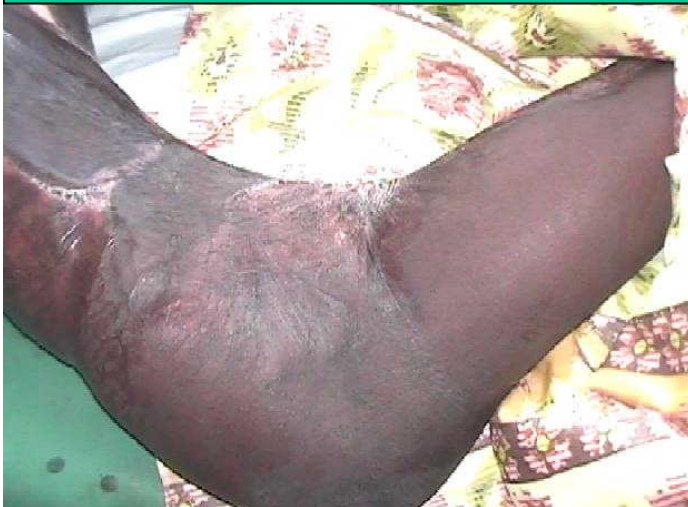
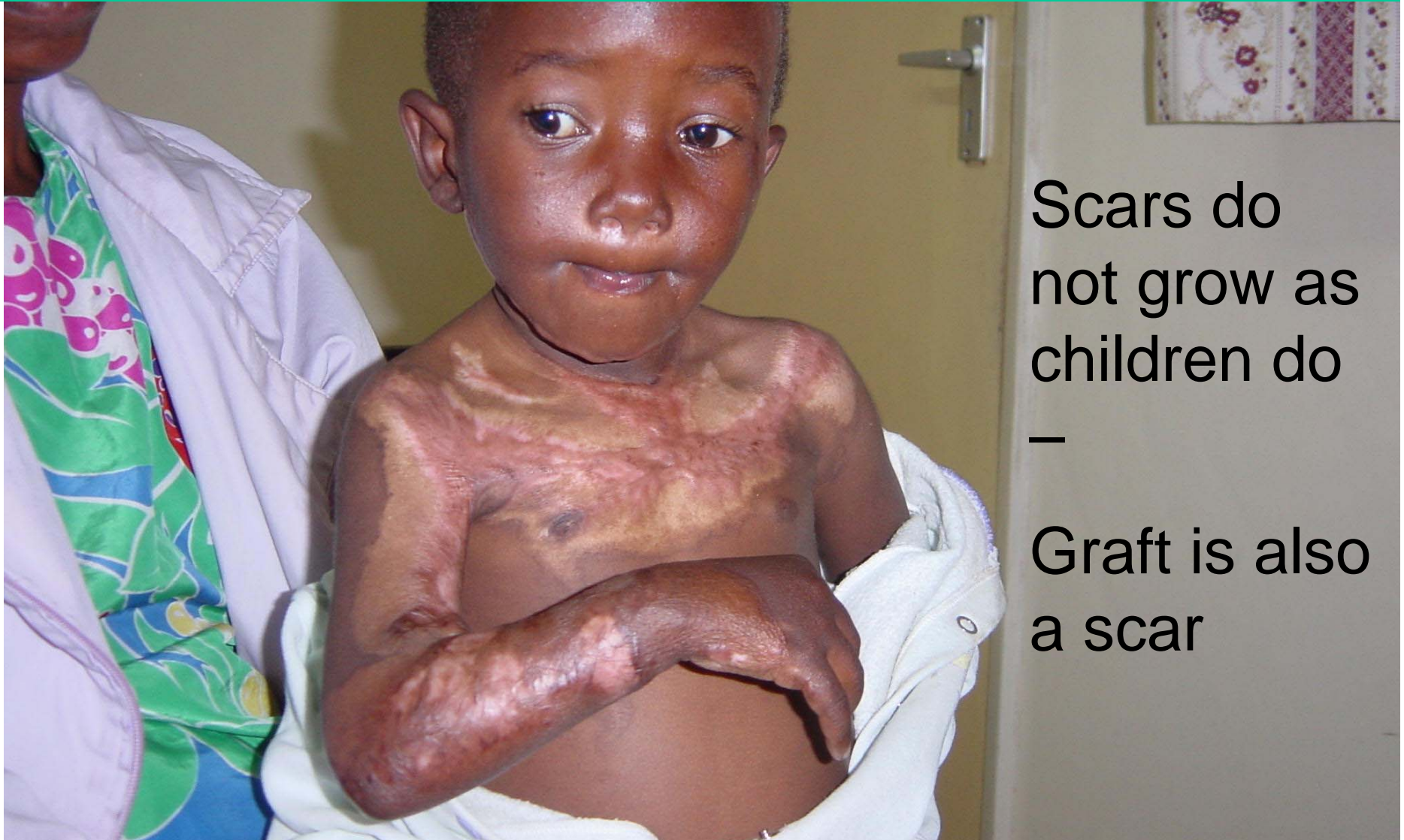Kenya, Nazareth Hospital

Leg contracture-Surgery: Transposition flap



In the following case of severe arm contracture we made a five limbs transposition flap in flexor area and thin grafts in distal areas



Scars do not grow as children do

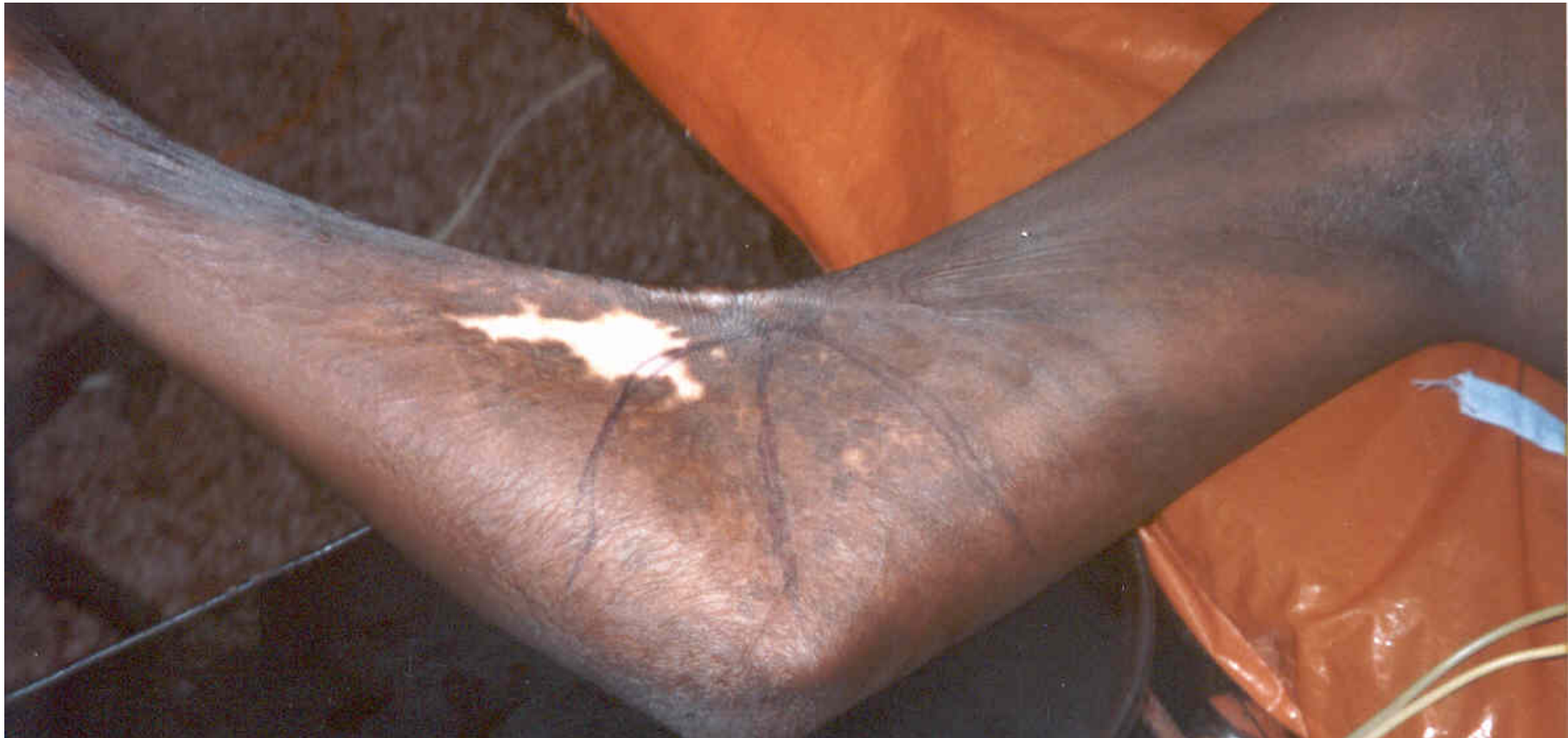—

Graft is also a scar

Tissues infiltration

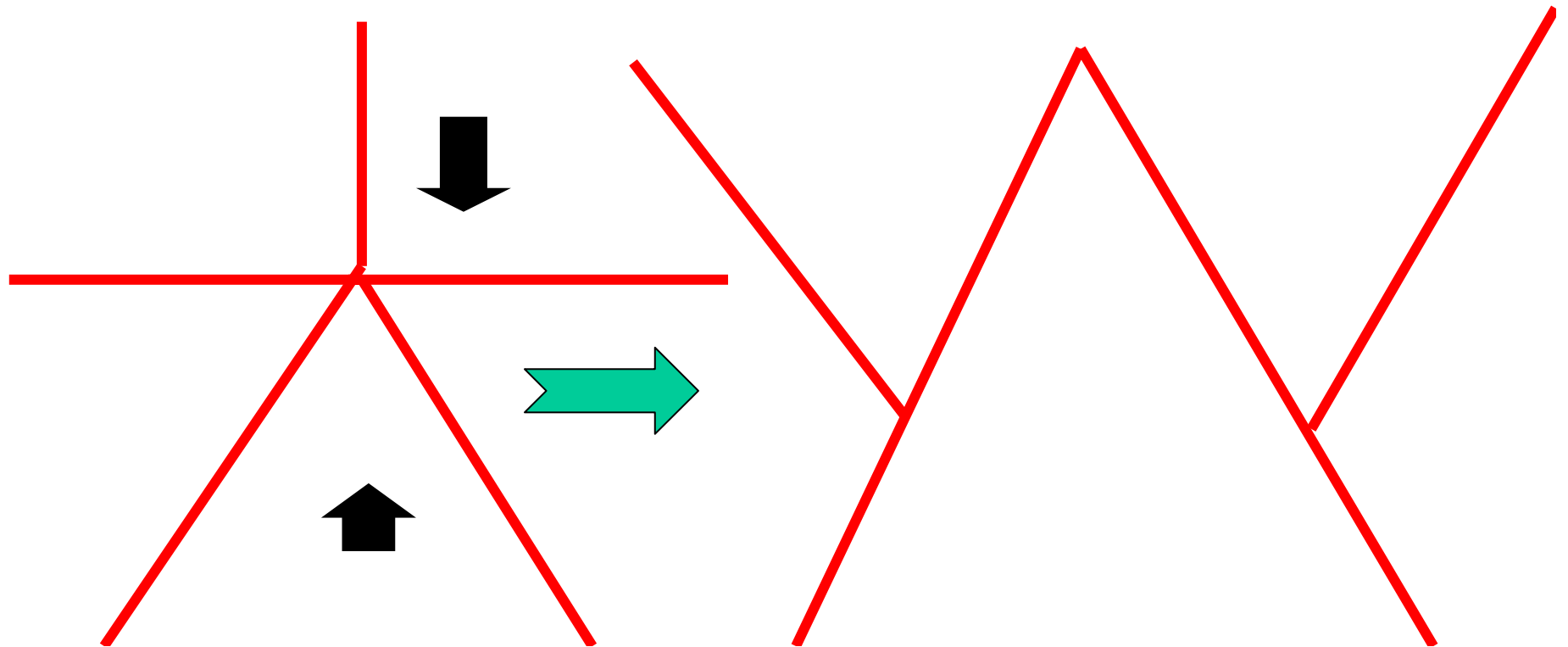
Injectable adrenaline 1:500,000
2 mg adrenaline in 1000 cc saline

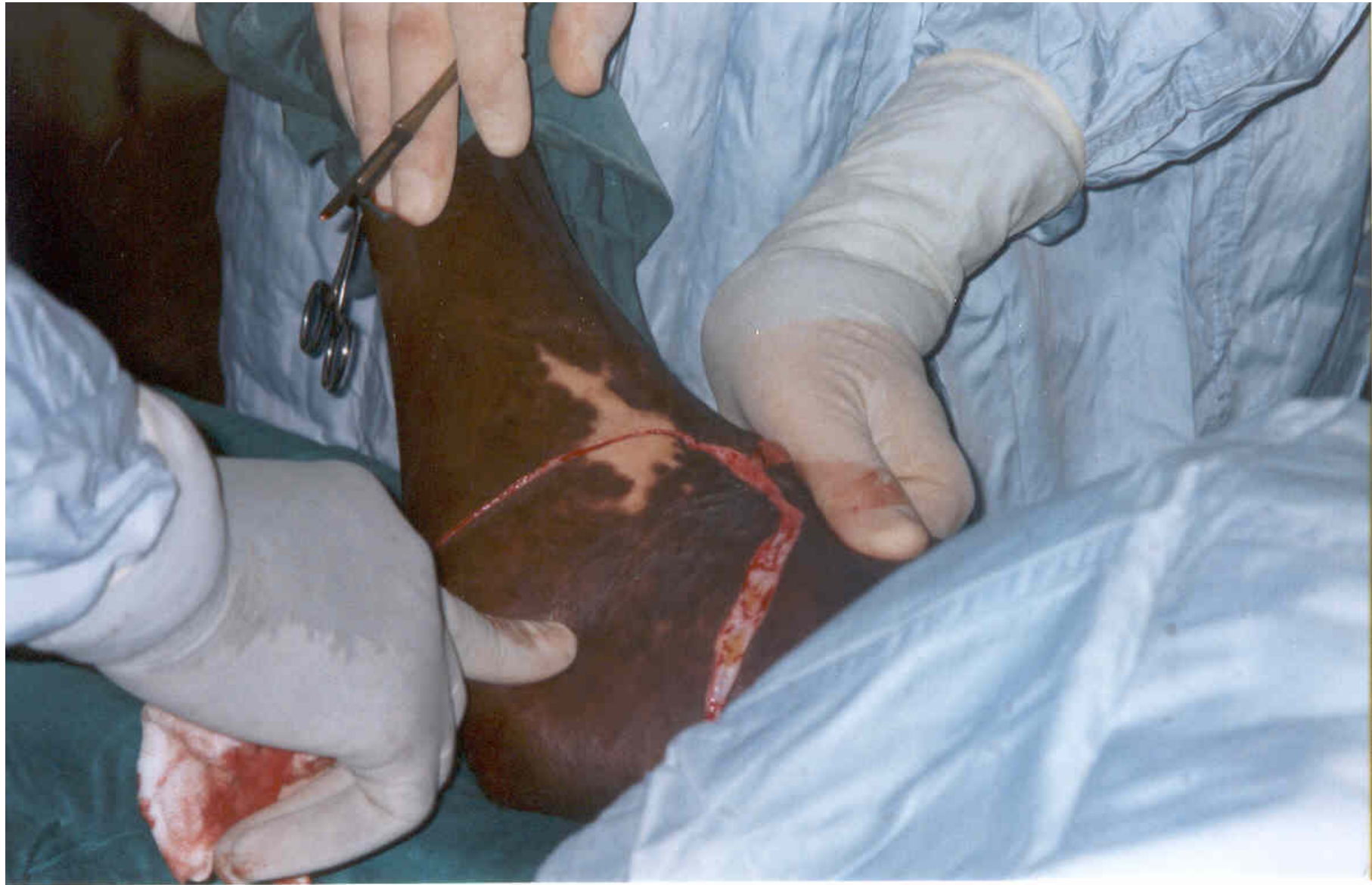Topical adrenaline
1:33,000
30mg in 1000 cc saline

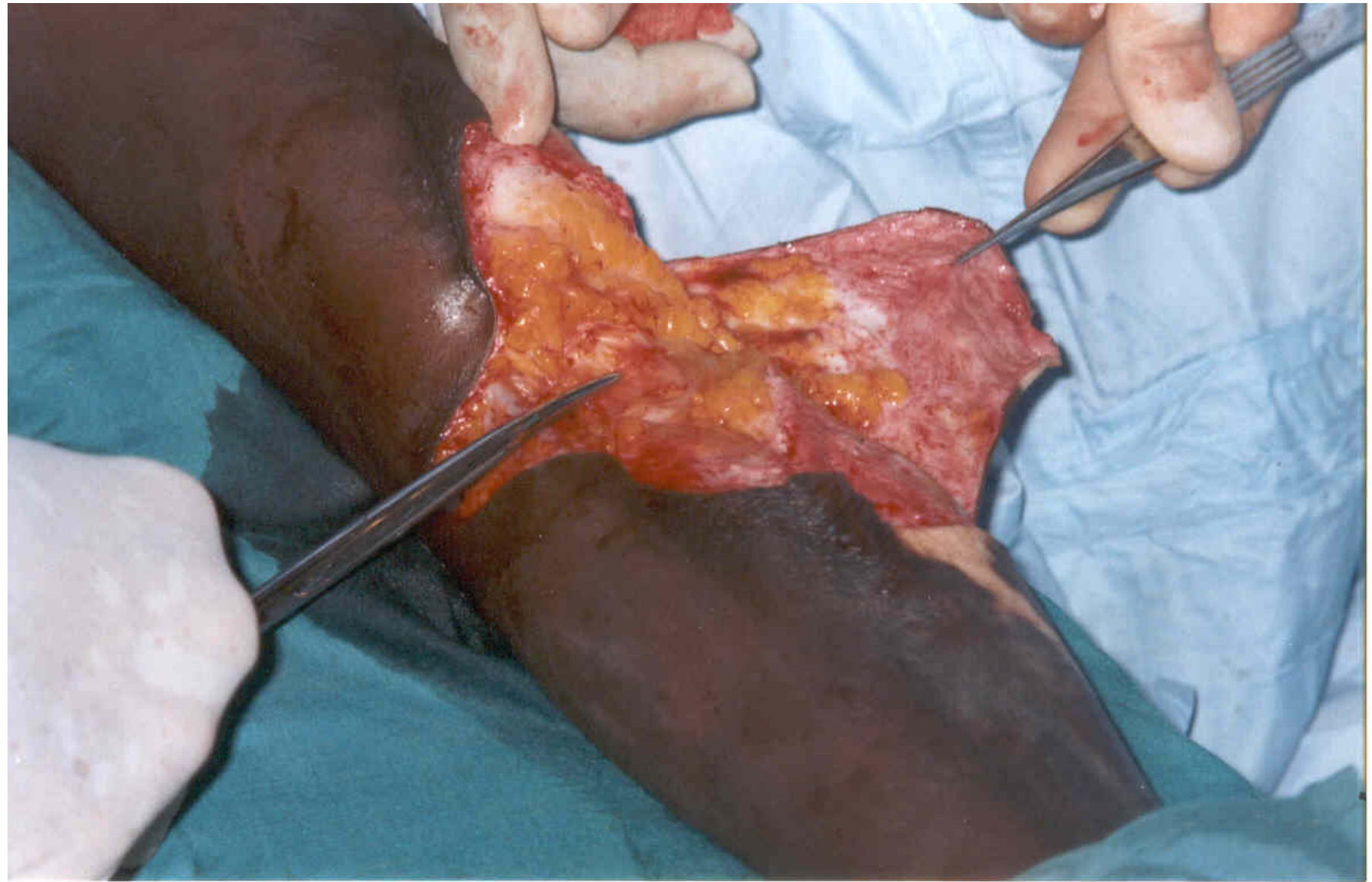


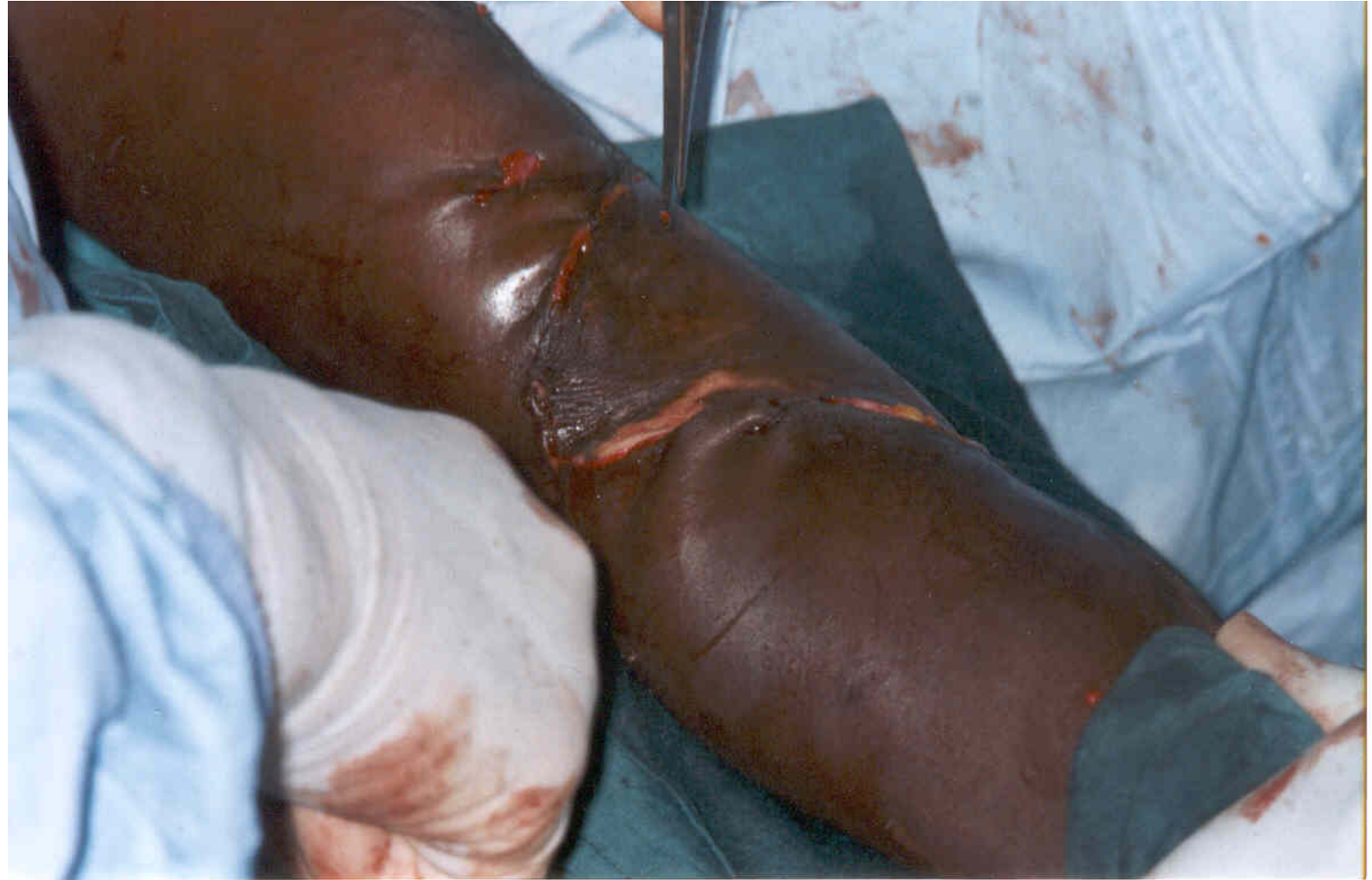In less severe contracture we were using a simple flap, composed by an advancement flap modified by two lateral discharging incision, as you can see in the following pictures. The patient is a young woman (26 old) burned by boiling liquid in Sierra Leone.

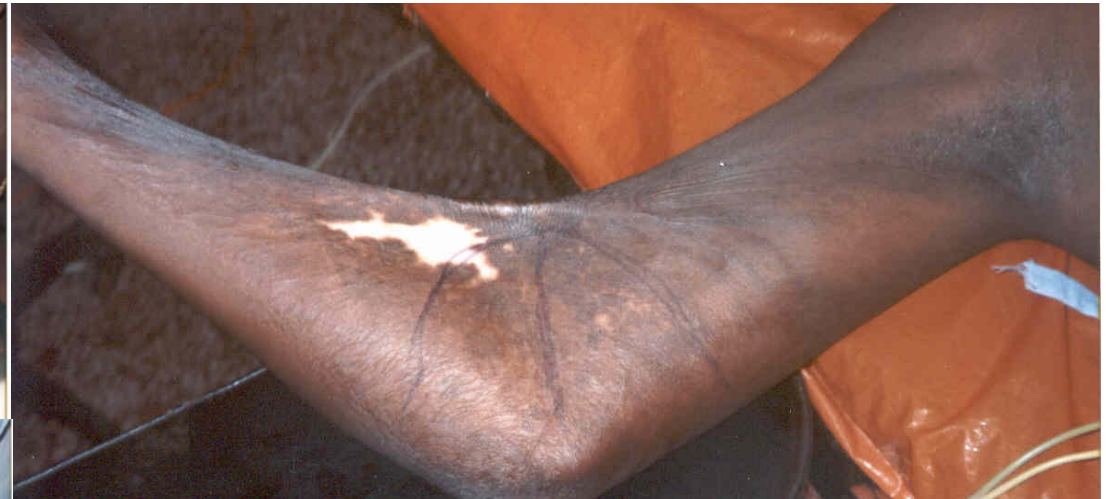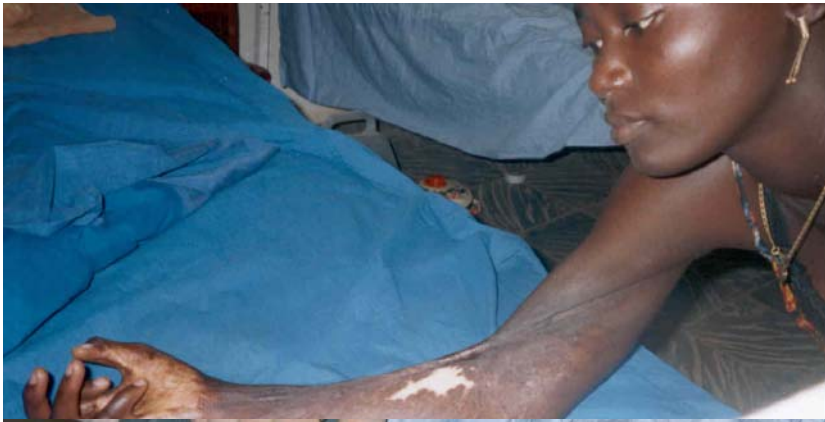Y to V Advancement flap with lateral discharging branches



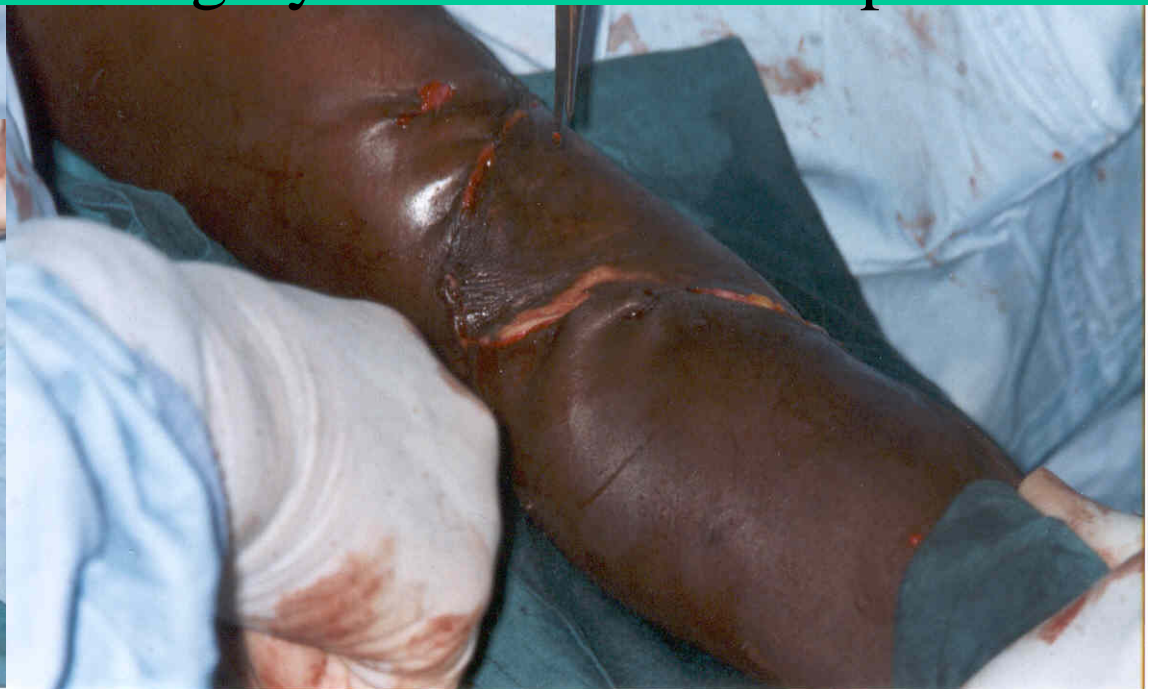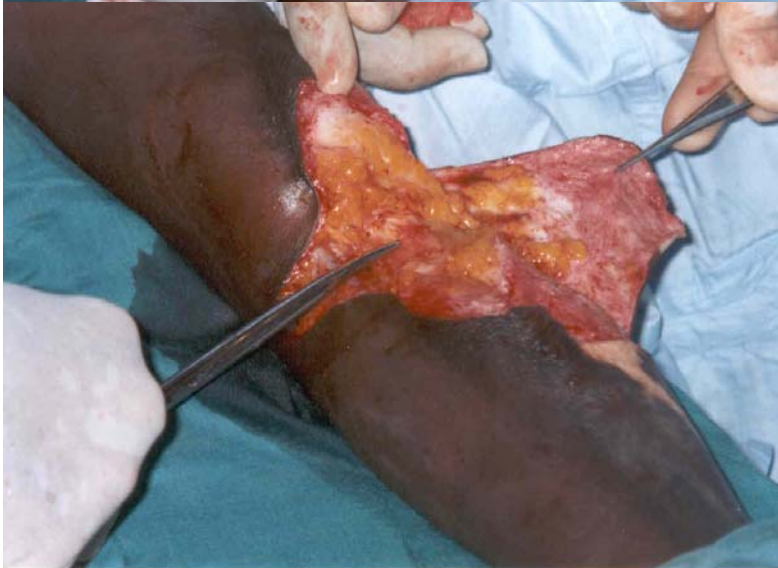

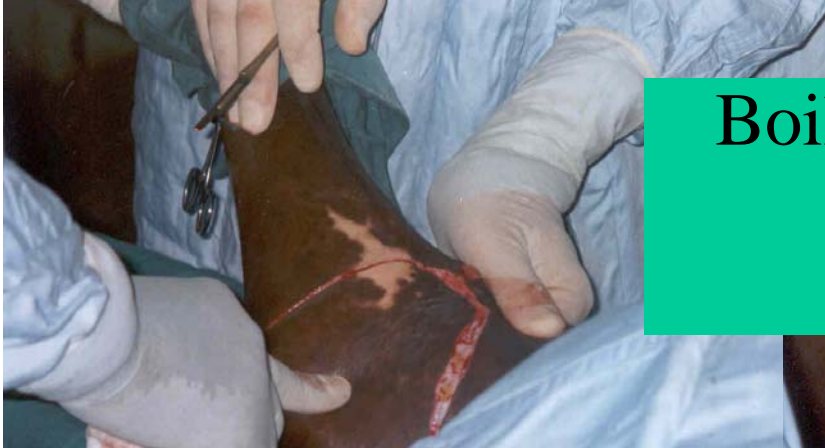




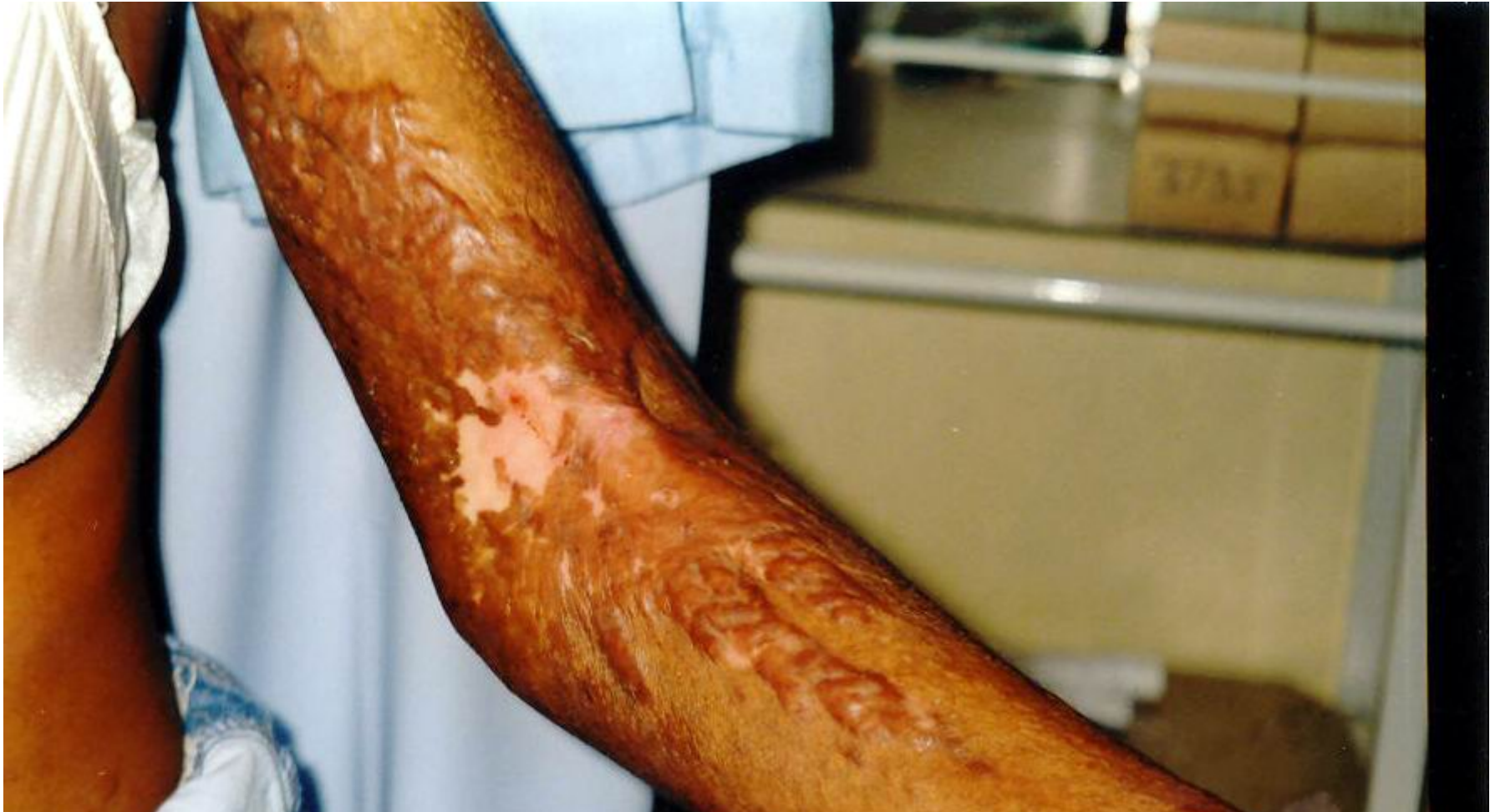

**Boiling liquid burn arm contracture in
Sierra Leone
Surgery: advancement-flaps**

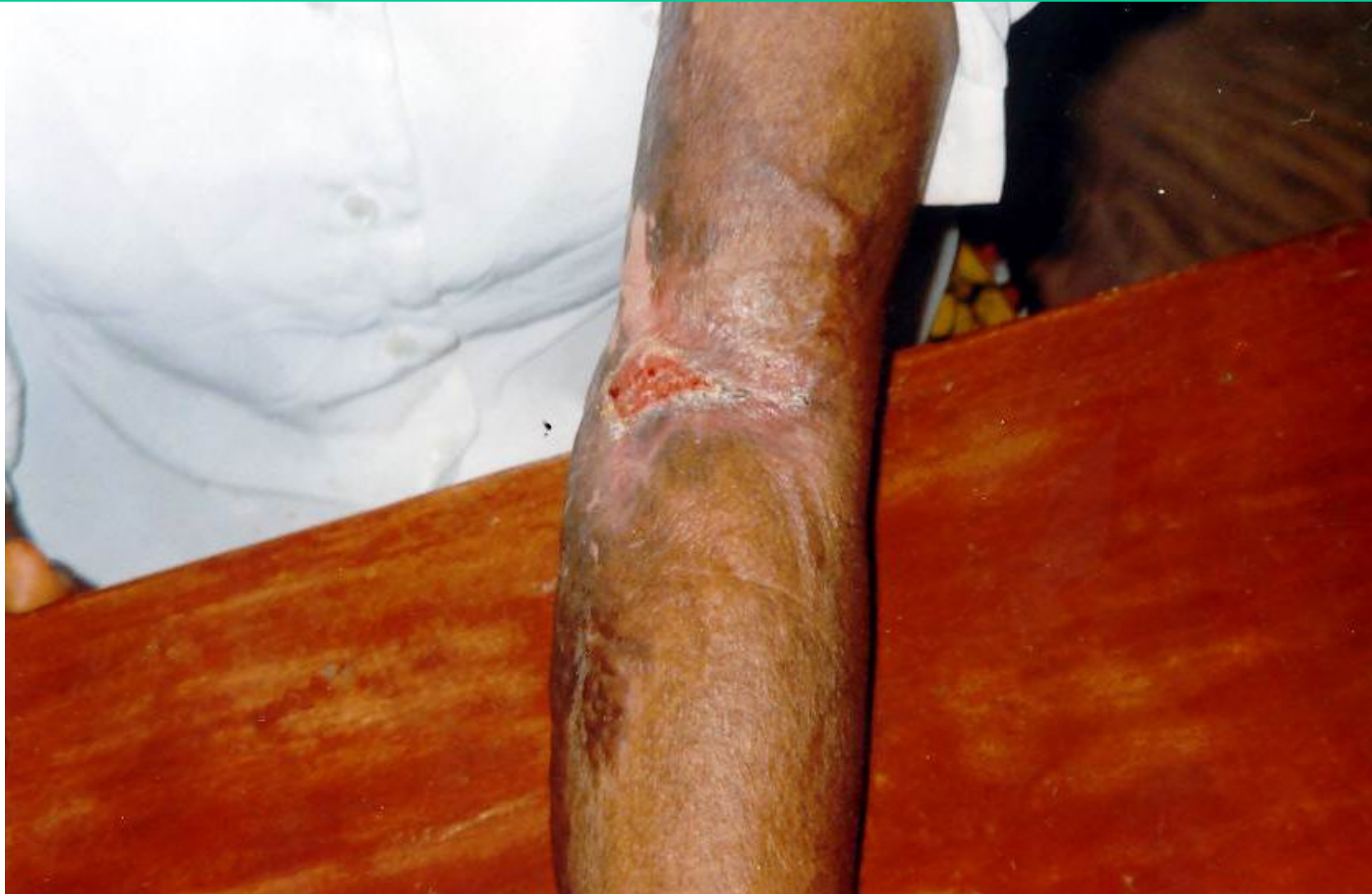

Lungi – Sierra Leone-Fire Burn Contracture



If this kind of intervention(transposition flaps) is not performable due to an extensive damage of the local tissues we transplant extremely thin skin, rather than thick, even in joints areas.

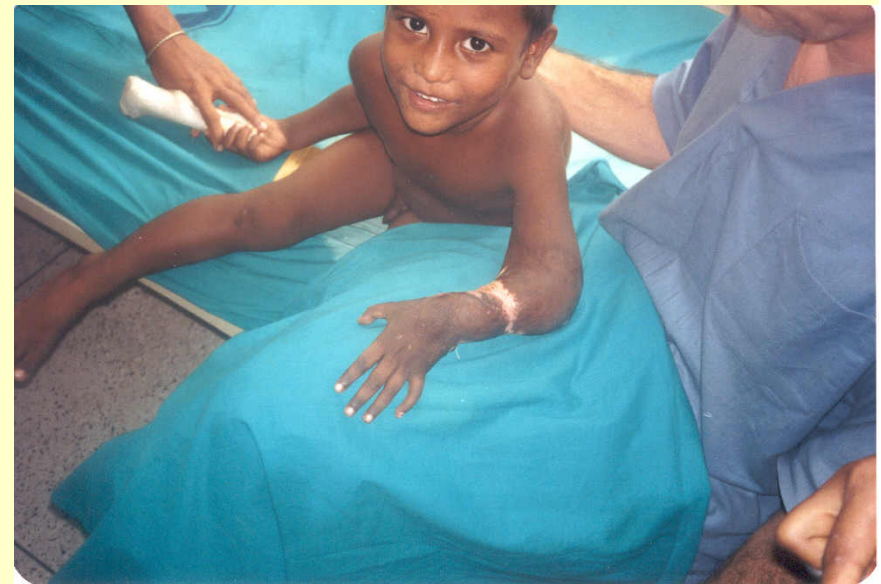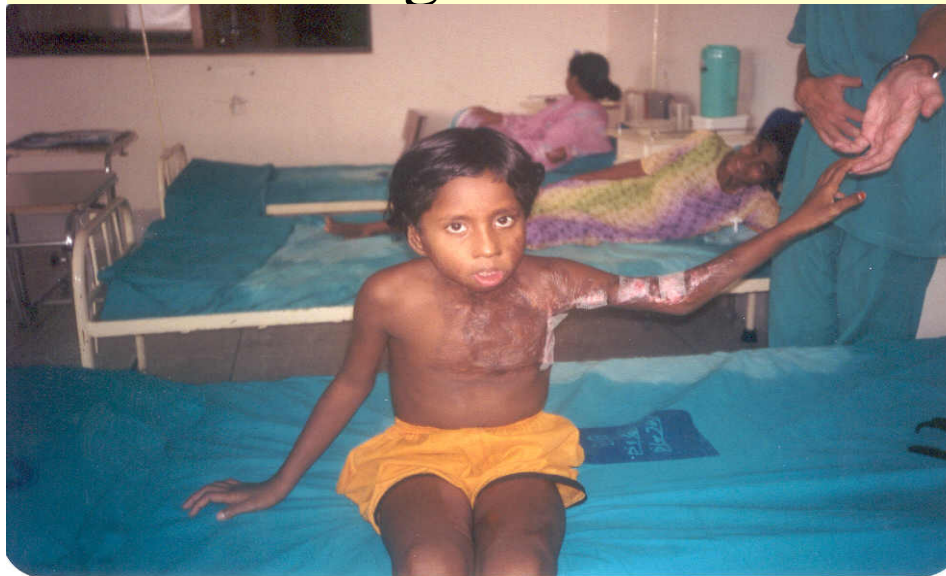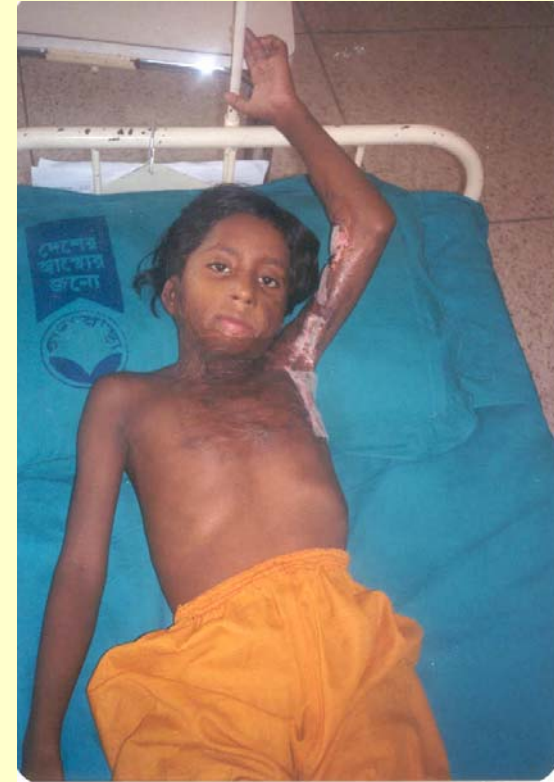Furthermore, really thin grafts adhere quickly to the area and, by early mobilization, they stimulate an increase of the connective tissue even in joint areas. Besides this kind of intervention guarantees better cosmetic results. Sometime occurs disepithelization in a small area, as in the picture, which is going to heal quickly, without problems.



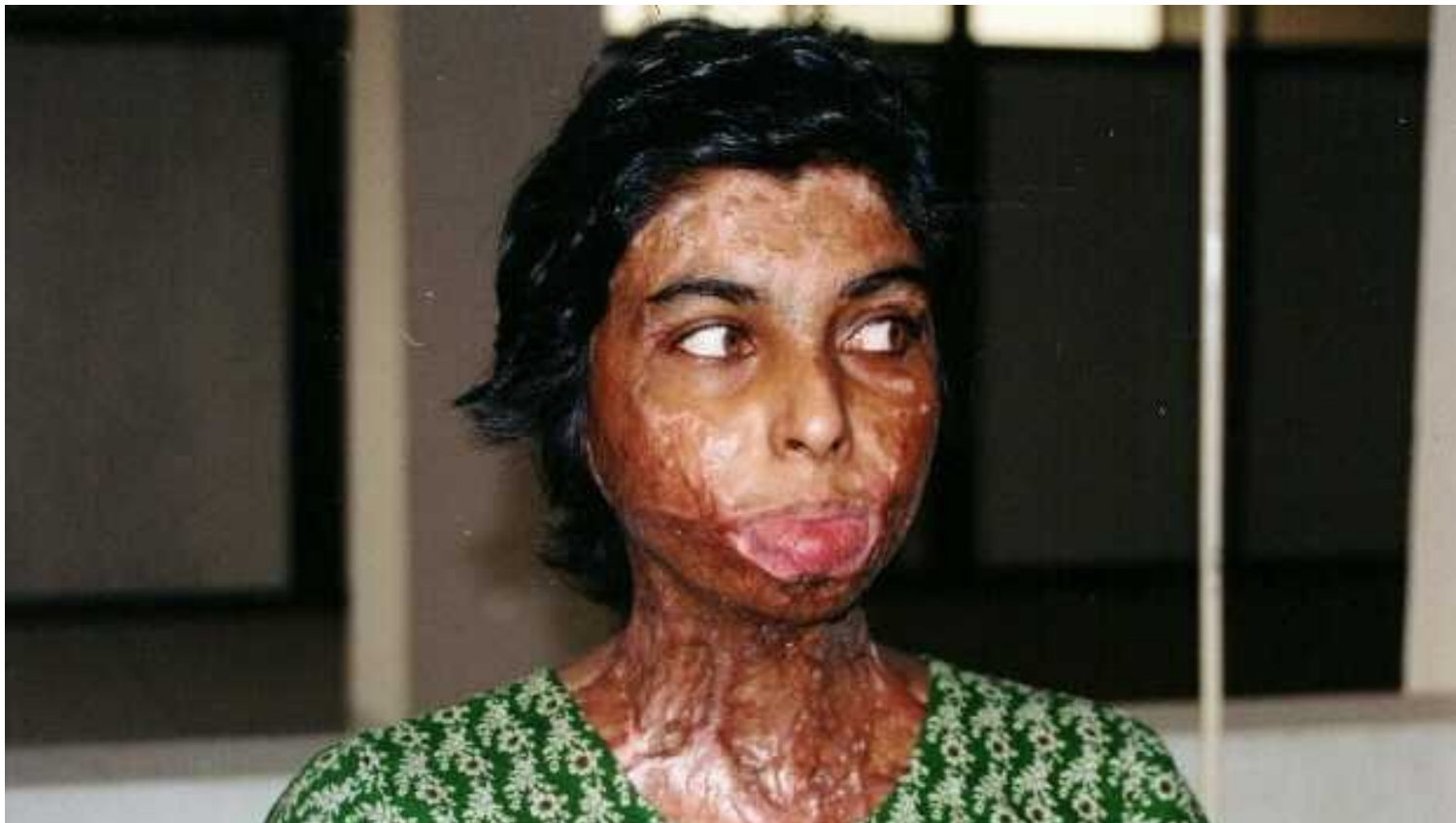The pre-operative and post-operative care was the most important part of all our projects in burn reconstruction. The physiotherapist involvement starts the admission day and continues in the operative theatre as dressing and splints have to be tailored to the patient's needs. Thus we included in our projects a training program about basics in plastic surgery, nursery and physiotherapy.

Rehabilitation

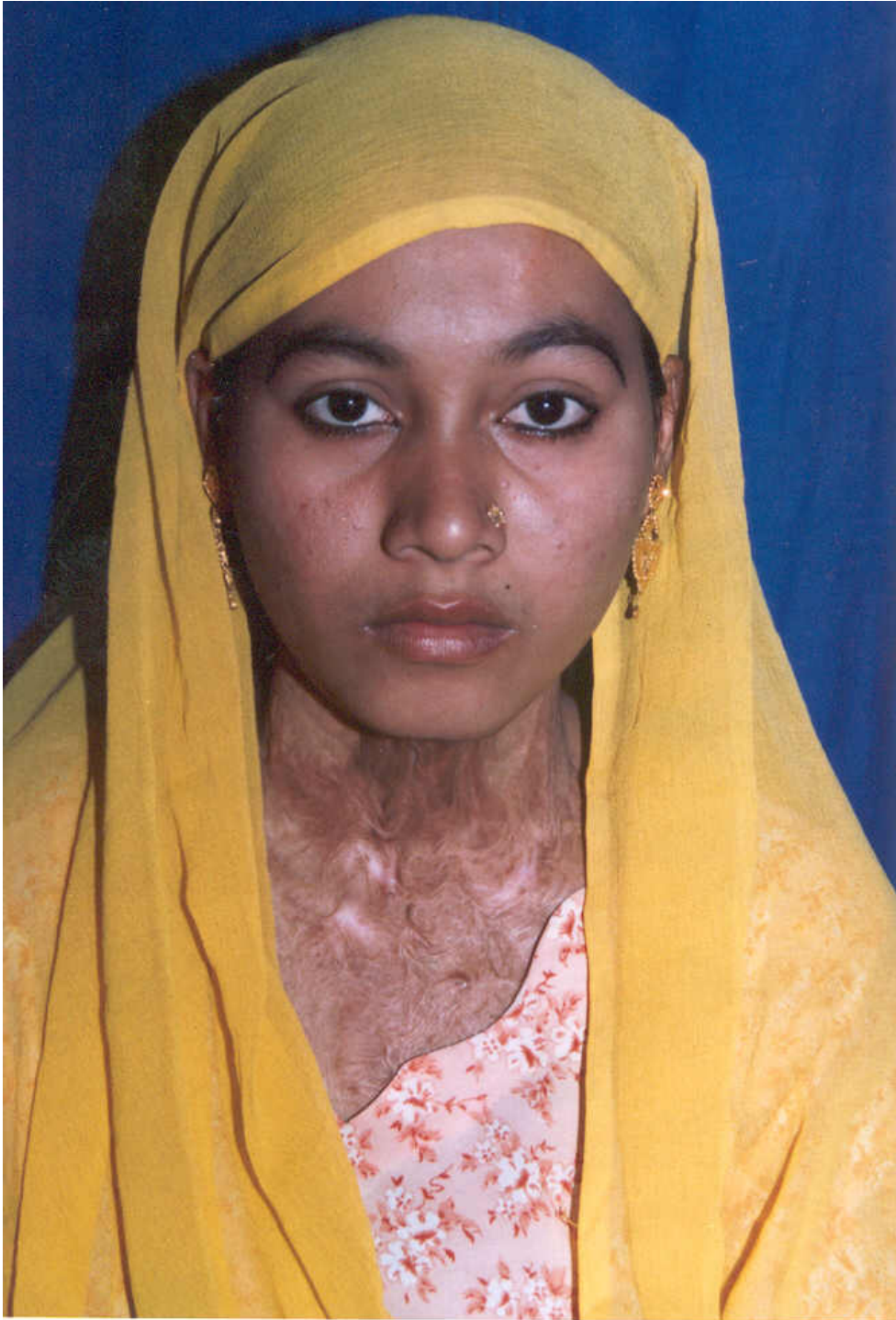- Mobilize as soon as grafts are stuck
- Elastic bandage to reduce swelling
- Aggressive out-patient therapy
- Pressure garments



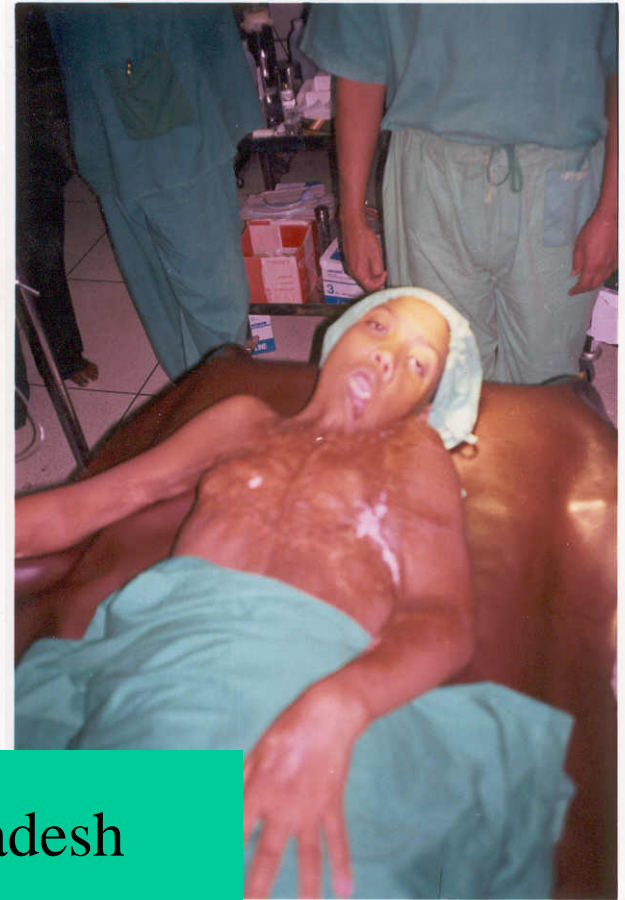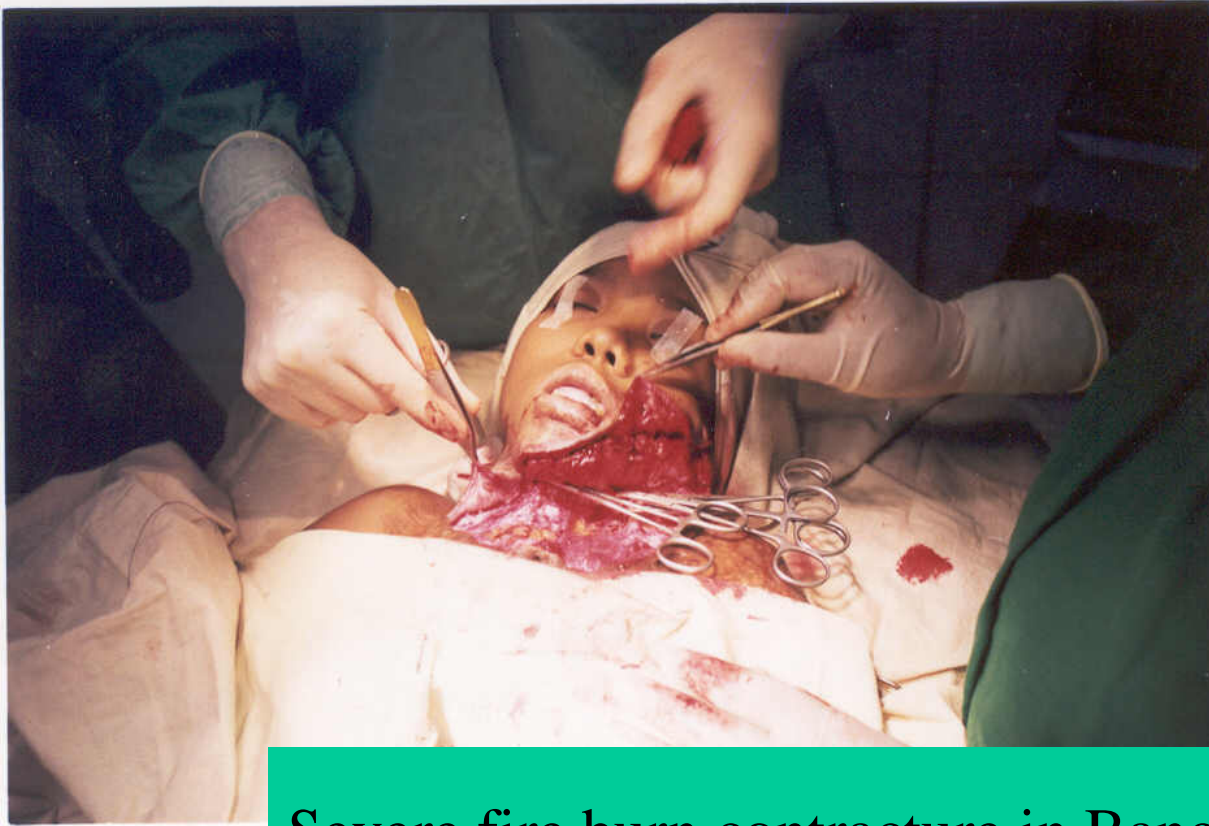
We have applied the above-mentioned technique with thin grafts even in young women with disfiguring and retracting scar on the face, as during the project for acid victims in Bangladesh.



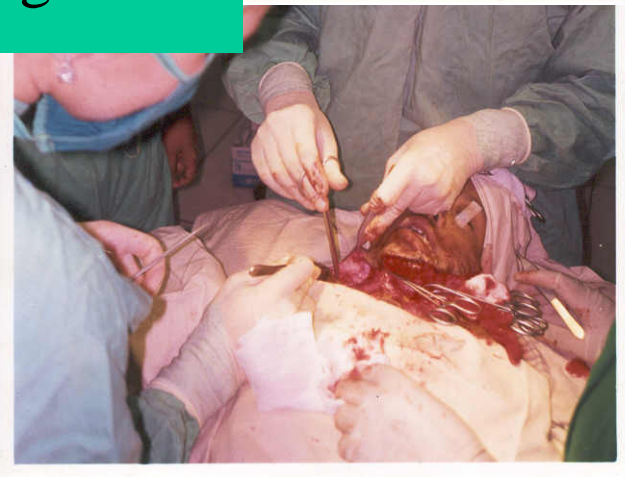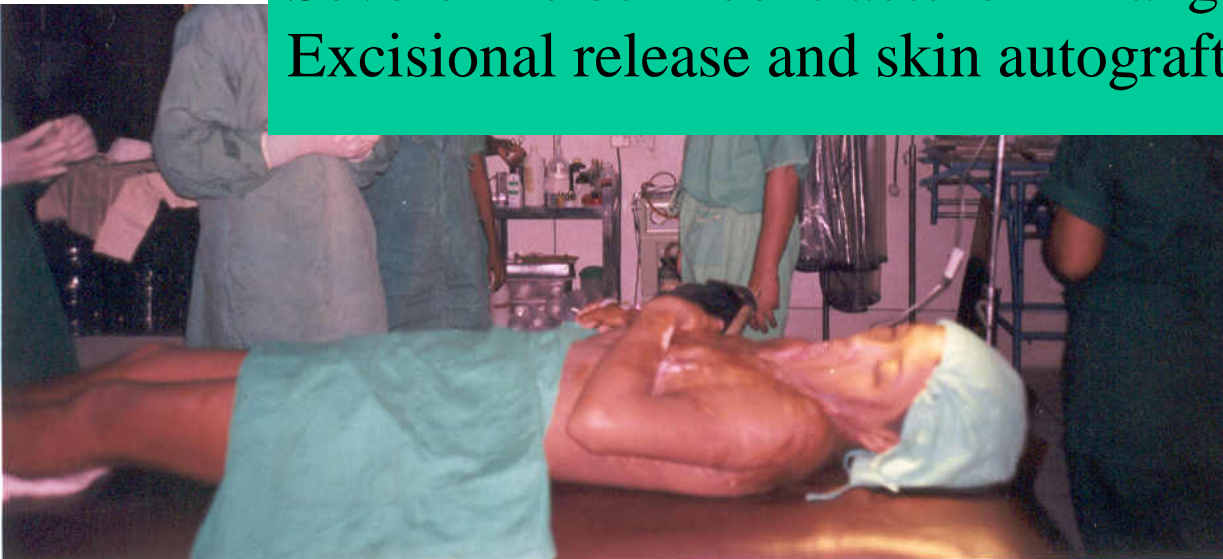Neck and mouth contracture



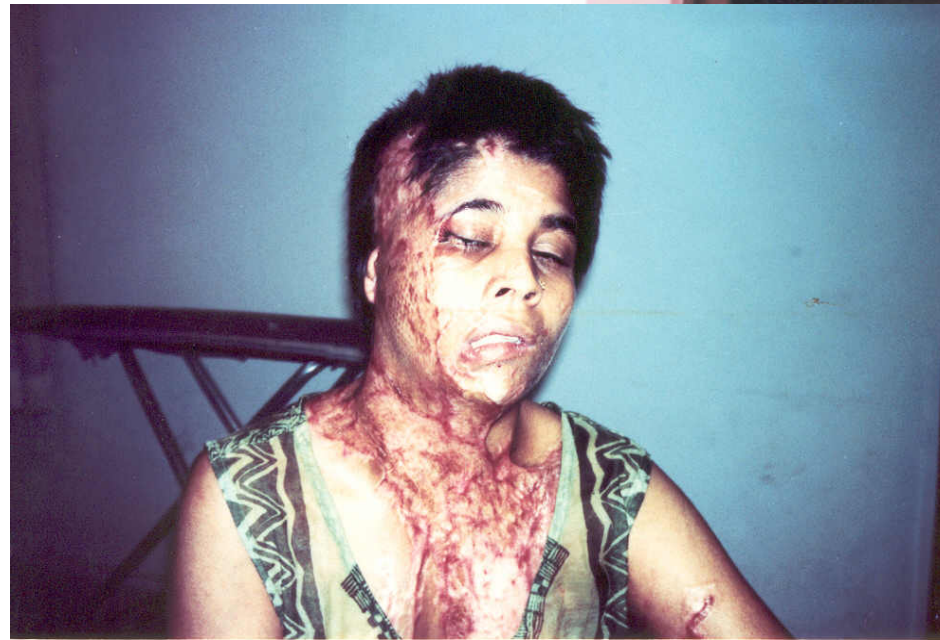
Acid Burn neck contracture



Severe fire burn contracture in Bangladesh
Excisional release and skin autografting



Neck contracture, lip ectropion
and mouth commissure deformity

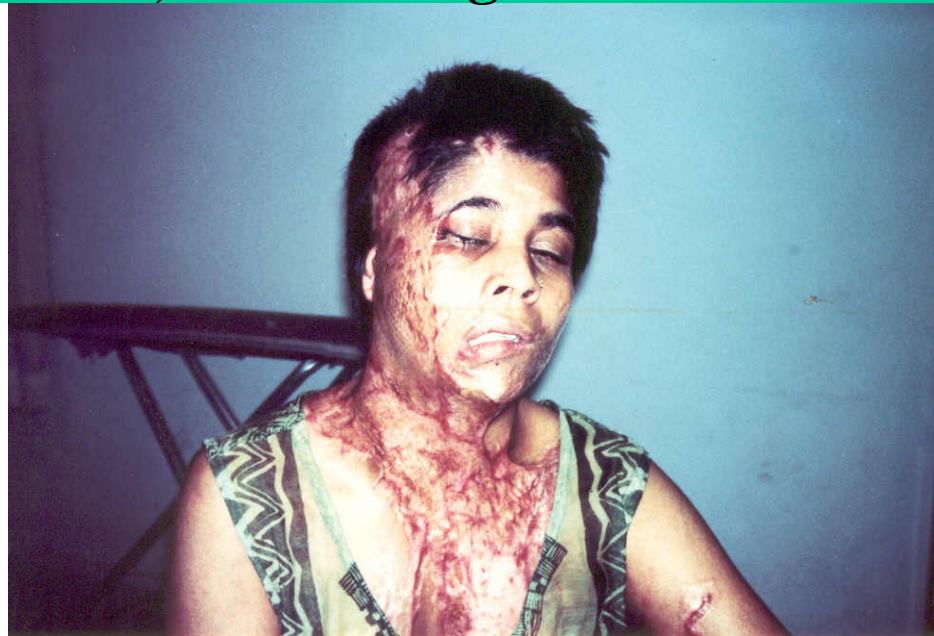

Neck excisional release and thin
skin autografting, commissural
local flap

The technique we used for most of the disfiguring scars was the tangential excision, by knife or by dermatome, until a viable bed is reached. Especially on the face is requested a special care to make a uniform bed surrounded by regular borders.

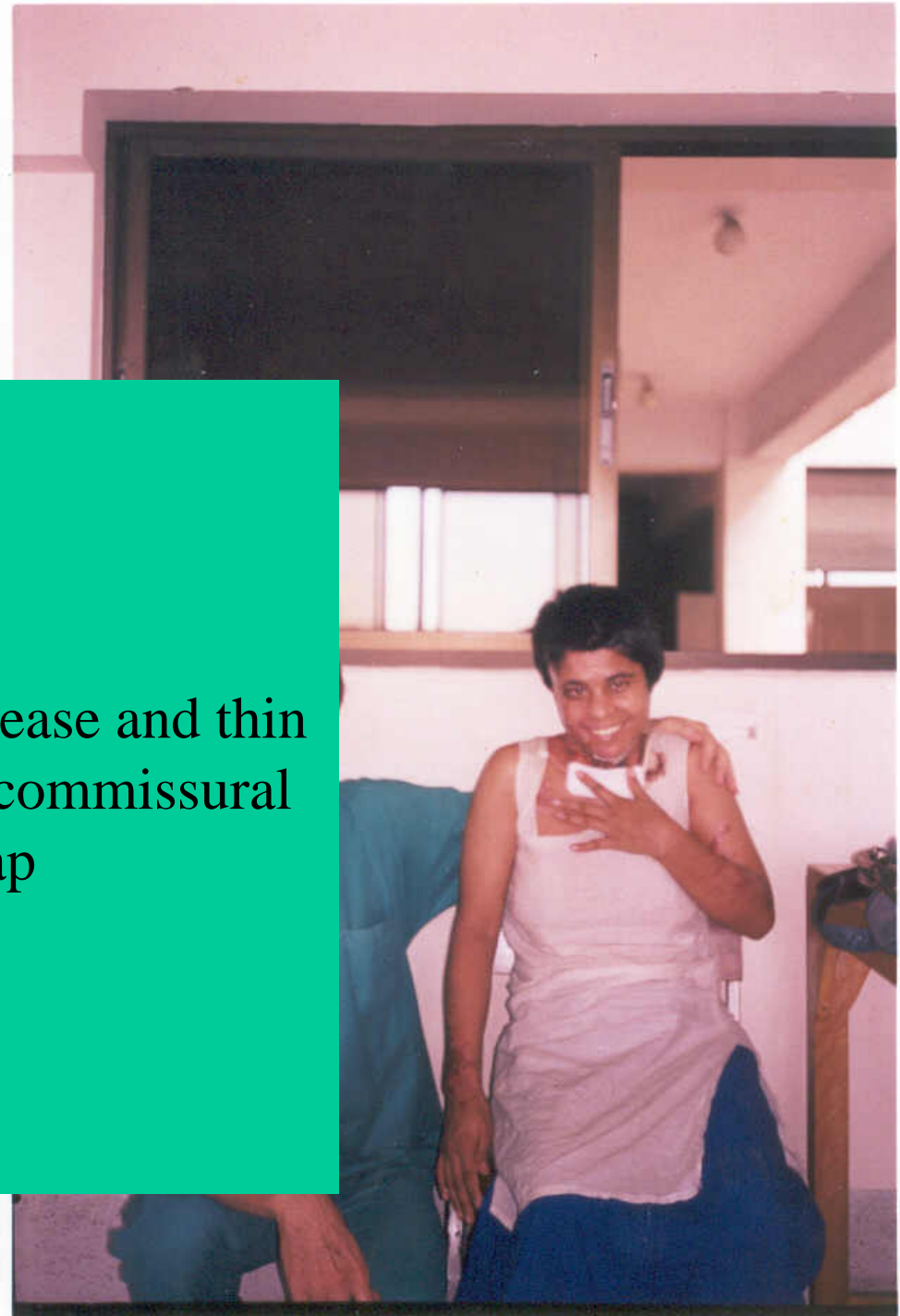To minimize the blood loss we were using a topical adrenaline solution:

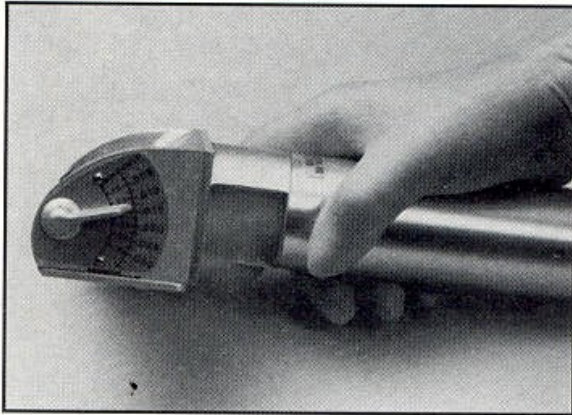
1:33,000 = 30 mg in 100 cc saline.



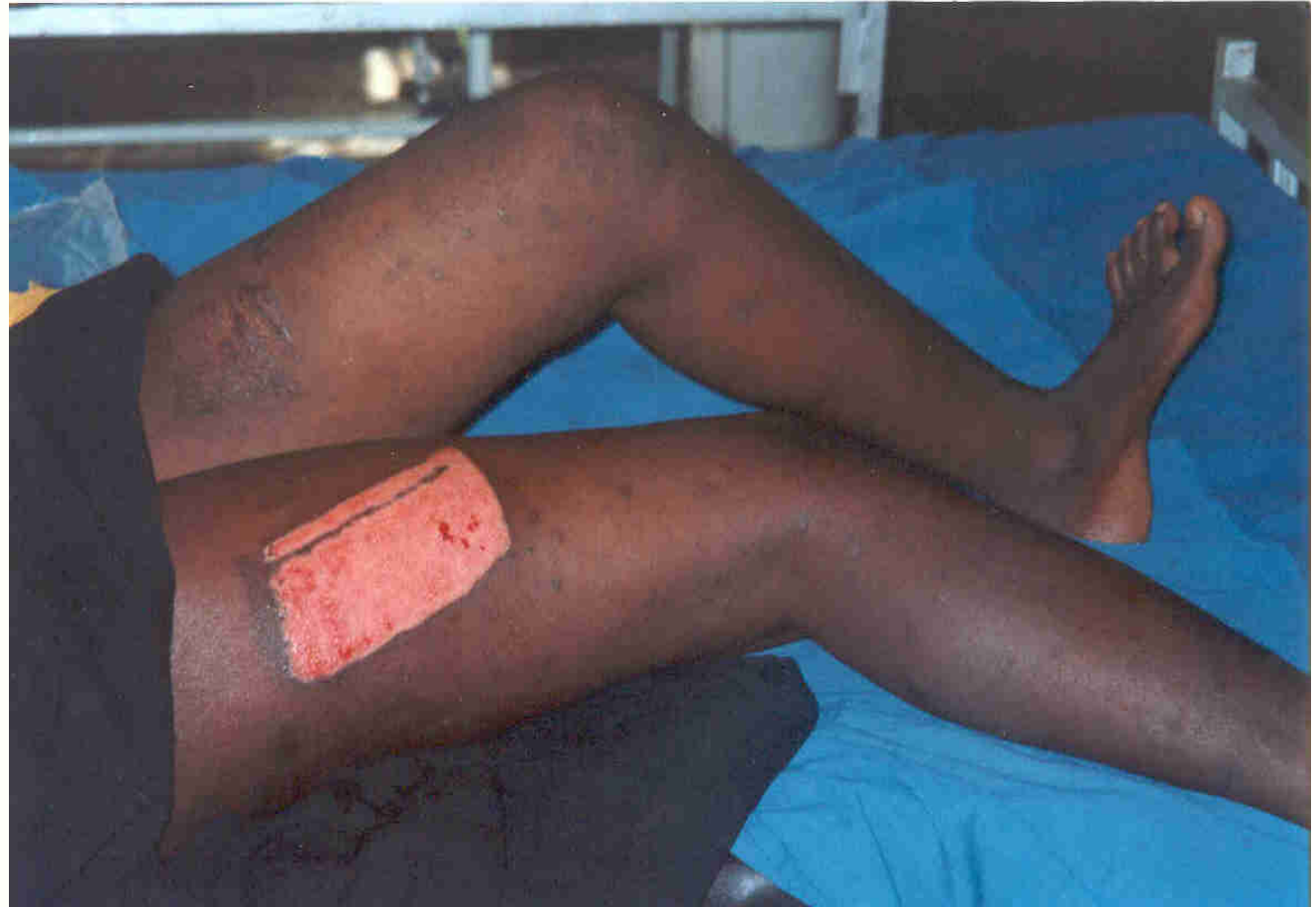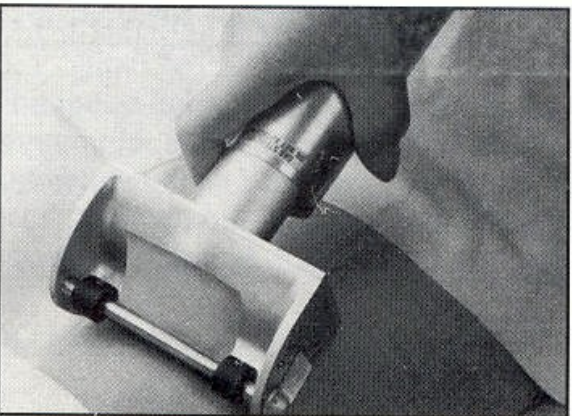
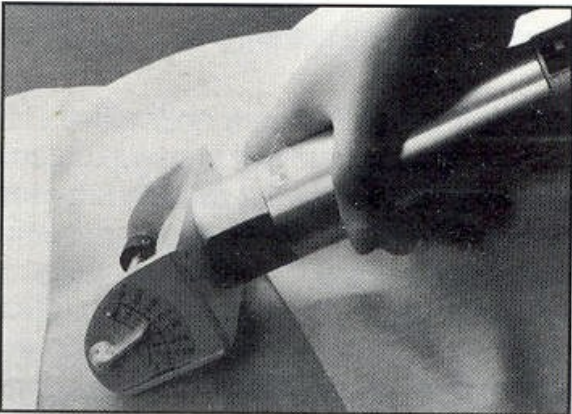
Neck contracture, lip ectropion and
mouth commissure deformity

Neck excisional release and thin
skin autografting, commissural
local flap

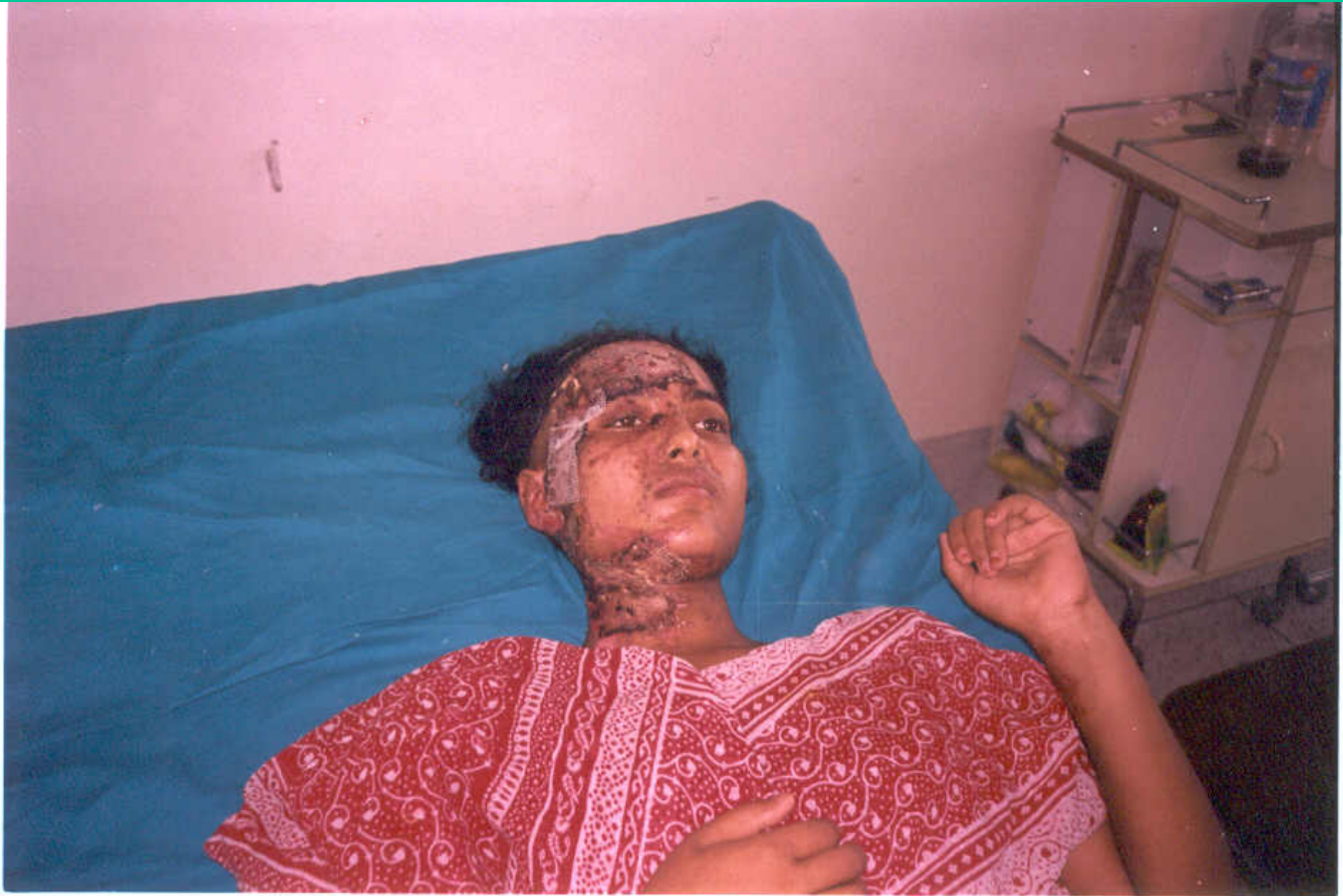



These thin grafts have to be removed with high precision preferably by electric dermatome, and then have to be applied with the same precision, without any suture. Steri-strips can be really useful in fixing them. A proper compressive wrapping and an early mobilization of the interested area are extremely important.



Thin grafts on the face

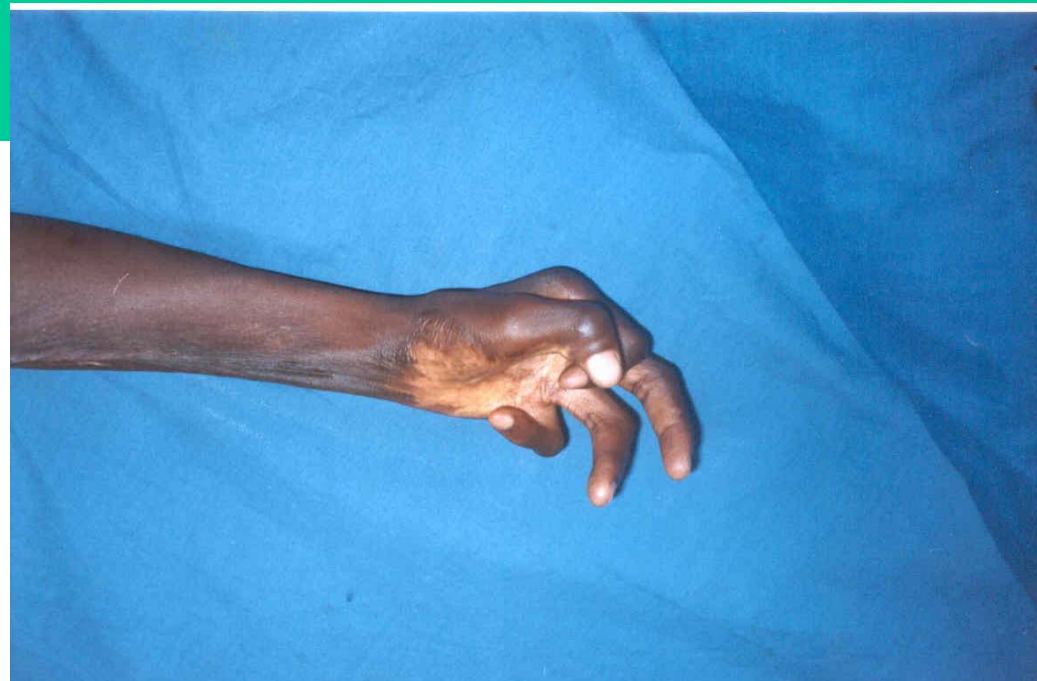

Hand major burn contracture

42 cases, 17% of all burn surgery performed were hand contractures. Our conduct in hand surgery:

- **Thin grafts whenever possible**
- **After surgery the hand has to be splinted with metacarpophalangeal joints flexed at 70-90°, the interphalangeal joints at 180°, the wrist slightly extended and the thumb flexed and adducted at the metacarpofalangeal joint**

Early mobilization, 4-5 days after surgery



The End